

Transformation of Ulcerative Colitis to Crohn's Disease: A Case Report and Literature Review

Satish Chandra Yadav¹ and Bingqiang Zhang^{2,*}

Abstract

The transformation of Ulcerative colitis to Crohn's disease is not frequently observed in clinical practice. In the present case, a 61-years old man underwent colectomy for Ulcerative colitis. The postoperative pathological finding reports showed the ulcerative colitis progressed into Crohn's disease. This is the first report of the accidental finding of CD in a patient underwent surgery for UC in the Chongqing medical university first affiliated hospital. Although most of the clinicians view both diseases as two different entities, present case views Crohn's disease as a continuation of Ulcerative colitis.

Keywords: Ulcerative Colitis; Crohn's disease; Colectomy

Abbreviations: IBD: Inflammatory bowel; UC: Ulcerative colitis; CD: Crohn's disease; CMV: Cytomegalovirus

Received: December 30, 2020; **Accepted:** January 22, 2021; **Published:** January 29, 2021

Introduction

The two major types of inflammatory bowel diseases (IBD) are UC and CD [1]. Abdominal pain, diarrhoea, GI bleeding, intestinal fistula, perianal disease or abscesses are the most common presentation of inflammatory bowel diseases [2]. The few IBD patients can present with atypical extra-intestinal symptoms involving musculoskeletal system, skin, hepato-biliary, or ocular systems [3]. Inflammatory bowel diseases are diagnosed with history, gross examination with colonoscopy and microscopic examination [1]. Both UC and CD present with similar symptoms but pathologically they are different so many authors view both diseases as different entities. Here we are going to describe a case report and a literature review where Ulcerative colitis progressed into Crohn's disease and both diseases are not two different diseases but the continuation of another.

Case Report

In 2013 (9 July), a 61-year-old man was transferred from periphery hospital to the Department of gastroenterology of the Chongqing medical university first affiliated hospital with the history of bloody diarrhea, 5-7 episodes per day, abdominal pain, abdominal distension, vomiting, tenesmus, dizziness and weight loss more than 4 kg for about 4-weeks. The patient condition did not improve despite blood transfusion, Nutritional supportive therapy, antibiotics and acid-suppressing drugs for 7 days so the

- 1 Department of Internal Medicine, Grande International Hospital, Kathmandu, Nepal
- 2 Department head of Gastroenterology, The First affiliated hospital, Chongqing medical university, Chongqing, P.R. China

***Corresponding author:**

JBingqiang Zhang (MD, PhD),

✉ zhbingqiang@163.com

Department head of Gastroenterology, The First affiliated hospital, Chongqing medical university, Chongqing, P.R. China, 400016.

Tel: +86-13114082507

Citation: Yadav SC, Zhang B (2021) Transformation of Ulcerative Colitis to Crohn's Disease: A Case Report and Literature Review. Med Case Rep Vol.7 No.1:2

patient was referred to our hospital. His pulse was 90/min, blood pressure 120/80, haemoglobin 11.8g/dl, and another clinical examination was unremarkable.

Colonoscopy was done and the report showed: inflammation of sigmoid colon and rectum. Five biopsy samples were taken, which showed: chronic mucosal inflammation with erosion, oedema, reduced goblet cells and presence of crypt abscesses (**Figure 1**). Based on History, physical examination, colonoscopy and pathology report ulcerative colitis was diagnosed. The patient was treated with oral mesalazine, enemas, and nutritional support, slowly patient condition improved over one week and the patient was discharged from the hospital, on oral mesalazine, and enemas.

In 2014 (September 11), the patient has admitted to Rongchang county people's hospital again with the history of diarrhoea mixed with mucus and blood for about 1 week. At that time patient gave the history that he stopped taking medicine by himself on the advice of his friends that he has fully recovered. He was fine for more than two months but got severe diarrhoea again, which did not improve on homemade (traditional) therapy. The patient was

treated with oral mesalazine, enemas, nutritional support and patient were discharged from that hospital on oral mesalazine, and enemas.

On November 11, 2015, the patient was again referred from local hospital to our hospital with a complaint of bloody diarrhoea for 2 weeks. His bowel frequency was 10-12 times per day, associated with significant abdominal pain, abdominal distension, tenesmus and weight loss of 2 kg. This time patient gave the history, that he changed the medicine from western medicine to Chinese traditional medicine, he was fine for more than 3 months but since last 2 weeks, his diarrhoea was getting worse, which was neither responding to Chinese traditional medicine nor to the western medicine. So the patient was referred to our hospital.

Colonoscopy was done on (2015-11-13), the colonoscopy report showed: chronic severe inflammation and hemorrhagic sigmoid colon and rectum. Six biopsy samples were taken, the microscopic finding showed: transmural inflammation, a large number of chronic inflammatory cells infiltration, erosion and oedema (**Figure 2**). CMV PCR test was Negative. Over the next 2 weeks, the patient was continued with mesalazine 4.8 g daily, 100 mg steroid enemas but there was no significant improvement in the clinical condition. After two weeks, high-dose oral prednisolone (60 mg) was added. After 3 weeks of hospital stay, patient bowel frequency was still 10-12 times. so we reviewed all laboratory investigations haemoglobin 77 g/l, C-reactive protein (CRP) 44.80 mg/l, white cell count (WCC) $26.51 \times 10^9 / l$ and albumin 25 g/l. erythrocyte sedimentation rate (ESR) 42 mm in the first hour, platelets (PLT) of $359 \times 10^9 / L$. stool test: red colour, watery, RBC > 60HP/field, WBC > 50HP/field. All other tests were unremarkable, including his thiopurine methyltransferase (TPMT) levels.

We changed the drugs to immunomodulators Azathioprine 2 mg/kg along with other supportive treatment for next two weeks. Even after 5 weeks of hospitalisation patient condition remained same. Sigmoidoscopy was on (2015-12-12), the gross finding showed mucosal ulceration, haemorrhage and a large number of deep ulcers, there was a high risk of perforation and potential to precipitate toxic megacolon so, we did not enter the Sigmoidoscopy more than 30 cm in the colon (**Figure 3**). We asked for surgical consultation, medical and surgical team decided to start Infliximab 5 mg/kg for next 10 days, at same time we did Contrast-enhanced CT scan of abdomen (CECT), report showed rectum, sigmoid colon, descending colon, transverse colon wall swelling, thickening, stratification and fuzzy fat, considered as inflammatory lesions (**Figure 4**). Despite all those treatment patient conditions was getting worse; so on the written consent of his family member on (2015-12-24) colectomy was done. The pathological specimen showed ulcer, haemorrhage, polyp and creeping fat (**Figure 5**). The histological report showed well-defined, epithelioid granuloma (**Figure 6**). Patient general condition improved after colectomy and was discharged on oral medicine after 3 weeks of colectomy. During follow-up patient was fine, there were no any symptoms and his stool examination and complete blood count were within normal range.

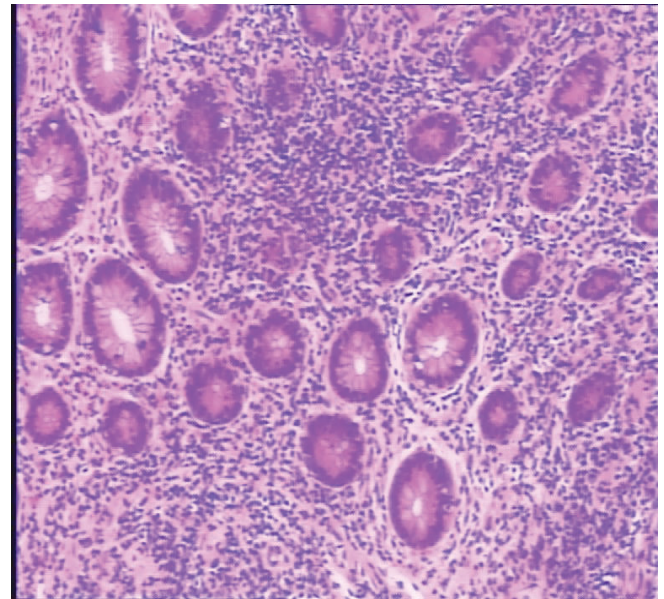


Figure 1 Chronic mucosal inflammation, irregular fossae, decreased goblet cells, and presence of crypt abscesses.

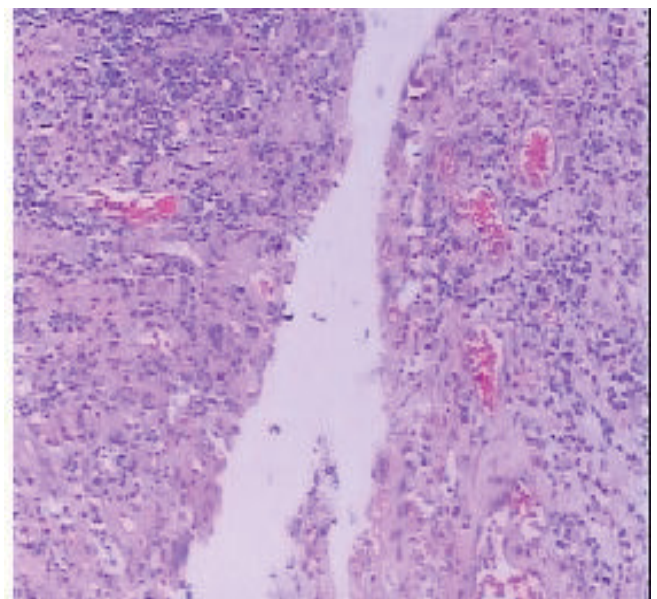


Figure 2 Transmural inflammation, chronic inflammatory cells infiltration, erosion and edema.

Discussion

Inflammatory bowel disease was more prevalent in America and Europe with the highest incidence in Faroe Island [4,5]. With the advancement in the treatment of IBD, most recent studies have shown that the incidence of IBD in the western country is constant [6-8] whereas the incidence of IBD in Asia and Eastern Europe have increased [9-12]. Ulcerative colitis is an Idiopathic chronic inflammatory condition that results in inflammation and ulcer of the colon and rectum [13,14]. The age onset of both the Inflammatory bowel diseases follows a same bimodal pattern,

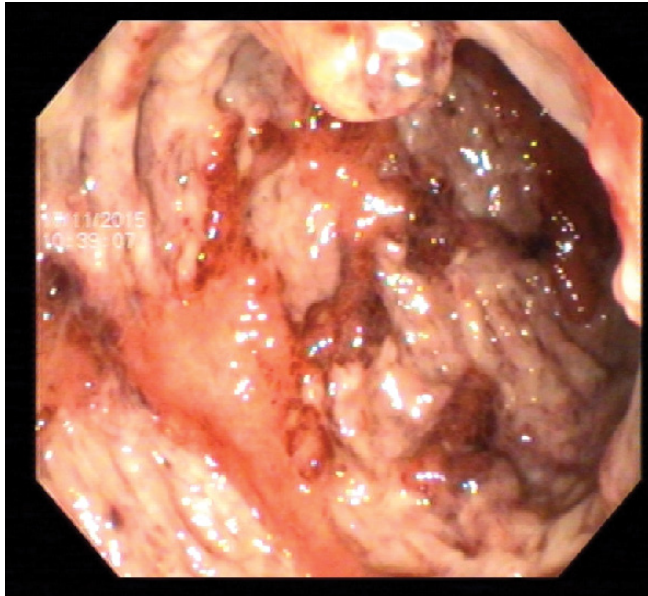


Figure 3 Mucosal ulceration, hemorrhage and a large number of deep ulcer.

and crypt abscesses [16]. In the present study, on July 9, 2013, biopsy showed mucosal and superficial submucosal inflammation and on (2015-11-13), it showed transmural inflammation. Even though transmural inflammation is characteristics of CD [17], it can be seen in severe UC case. In the present case, patients on the early visit had mild UC and later on visit had severe UC. Although the frequency of extra-intestinal manifestations has been reported between 6-47% [18] in the present case there were no any extra-intestinal symptoms.

In the present case Ulcerative colitis was diagnosed based on patient history, clinical symptoms, stool reports negative for bacteria and parasites, gross macroscopic appearance under

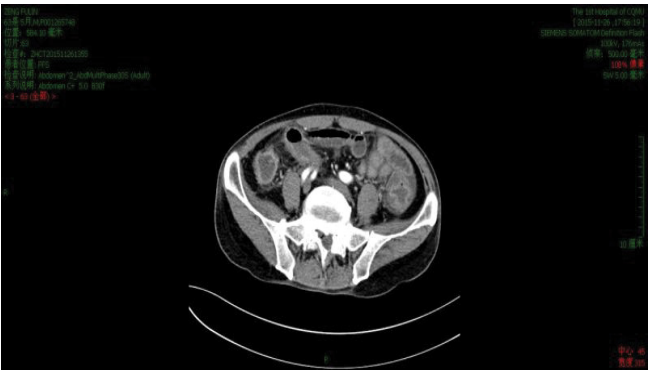

Figure 4 Rectum, sigmoid colon, descending colon, transverse colon wall swelling, thickening, stratification and fuzzy fat.

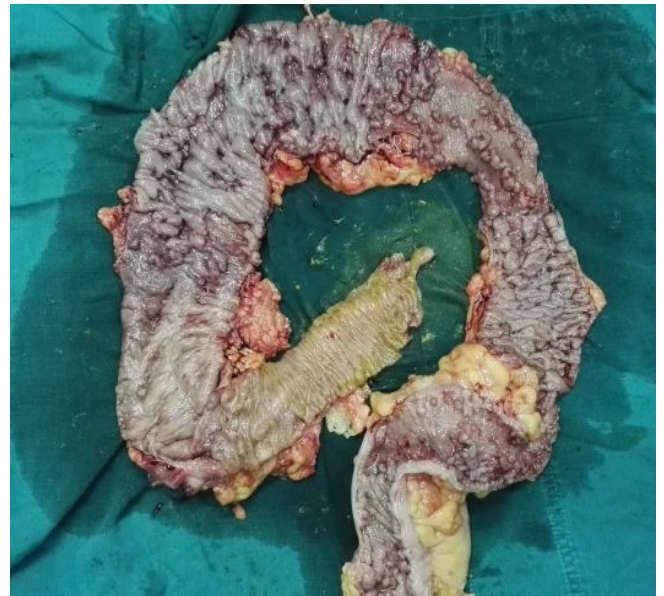

Figure 5 Specimen shows ulcer, hemorrhage, polyp and creeping fat.a

with greater peak ages of 15-30 years and smaller peak ages of 60-80 years [14]. In the present case, a male aged 61 years falls under the age group where small percentages of peoples are affected.

The major symptoms of Ulcerative colitis are diarrhoea mixed with blood or rectal bleeding, the passage of mucus, tenesmus and abdominal pain, fever and weight loss [15]. In the present case, the patient had similar symptoms on his visit to the hospital. The macroscopic features of Ulcerative colitis are erythematous mucosa, fine granular surface in the mild case and hemorrhagic, edematous and ulcerated mucosa in severe case [16,17]. In the present case, at the beginning colonoscopy finding showed mild UC but later on when colonoscopy was repeated it was already severe. Histologically, Ulcerative colitis is limited to the mucosa and superficial submucosa but in the severe case in can affect deeper layers with multiple mononuclear cells, polymorphonuclear leukocytes, distortion of crypt architecture

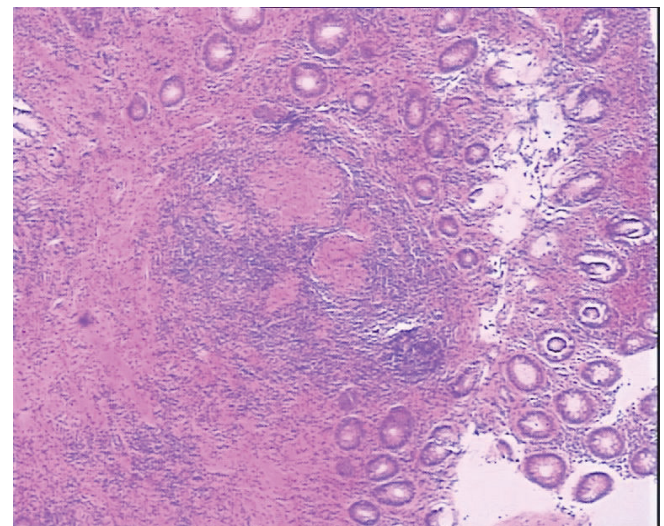


Figure 6 Sigmoid colon showing granulomatous inflammation.

colonoscopy and microscopic appearance of biopsy reports which is similar to the other study and is also the diagnostic criteria of UC [1]. CMV colitis can have similar manifestation but in the present case, CMV was negative in blood and PCR so CMV colitis was ruled out from the differential diagnosis.

In the present case, treatment Guidelines was followed According to American College of Gastroenterology, Practice Parameters Committee for UC [19]. According to this guideline mild to moderate case of UC should be treated with oral aminosalicylates, topical mesalamine, or topical steroids and/or a combination. The severe case of UC intractable to maximal oral treatment should be managed with infliximab, infliximab is effective in most of the cases and avoids the need of colectomy. In the present case patients failed to improve despite 10 days treatment with infliximab, According to the guidelines of the American College of Gastroenterology, patients failed to improve with infliximab is an indication for either colectomy or intravenous cyclosporine.

In the present case, our surgical and medical team decided to go for surgery. The indication for operation was long lasting illness, intractable to medical therapy, physically getting weak, unable to tolerate drugs adverse effects and psychosocial dysfunction. Patient and patient relatives were worried since they were admitted in hospital for more than one month. These are also the indication stated in American College of Gastroenterology guideline for colectomy in UC patient [19].

After colectomy, surgical specimen was sent for gross and microscopic examination, the macroscopic examination showed strictures, inflammatory masses, abscess and ulcers, the microscopic examination showed granuloma. Even though granuloma is pathognomonic for Crohn's disease, it can be seen in few cases of UC but the granuloma seen in UC have ruptured mucosal crypts (cryptolytic" granulomas) and granuloma seen CD are well-defined and epithelioid also called true granuloma [20,21]. In the present case, granuloma was well-defined and epithelioid. Since the granuloma is the cornerstone for the diagnosis of Crohn's disease in our clinical practice, most of the doctors change their diagnosis from UC to CD assuming that their previous diagnosis was mistaken.

In the present study, we finally diagnosed UC progressed to CD over long treatment duration. A similar case was reported in 1994 by AD Dwarakanath associated with corticosteroid treatment [22]. In the present case, the cause of transformation is unknown since the duration of treatment with corticosteroid was not as long as in Dwarakanath case study. We assumed Chinese herbs can be the cause of transformation since patient in present case took Chinese herbs for the treatment of UC but there are few studies which show that Chinese herbs can be used for the treatment of UC [23,24].

Most of the study view UC and CD as two different diseases of IBD but in contrast to this hypothesis, Present case views CD as the continuum of UC. The term intermediate colitis was first introduced by Kent et al. in 1970 [25]. In his retrospective study of 222 patients with IBD, 14 were diagnosed intermediate colitis post-surgery due to overlapping features of UC and CD. This

study shows that UC can progress to IC or from IC to CD since the features of IC is in intermediate to both the colitis. Vester-Andersen et al. conducted a prospective study, their study results showed among 513 cases, 28.7% cases of UC showed progression while 23.9% of patients with CD showed changes in disease localisation but none shows progression [26]. This study shows that CD cannot progress to UC but UC can progress to CD. A recent cohort study from Korea shows that among 1444 UC patients the final diagnosis was changed to IC in 0.4% and CD in 1.7% [27]. All these studies along with present study show that CD is the continuum of UC not a different entity of IBD.

Microscopically, colon and rectum are made up of four layers of tissues: Mucosa (innermost), Submucosa, Muscularis, Serosa (outermost) as shown in **Figure 7**. UC is confined to the mucosa and submucosa of the colon [28] whereas CD is characterised by transmural inflammation [29]. CD and UC are due to the disruption of tight junctions and the mucus layers which covers the intestinal epithelium. Increased recruitment and retention of effector macrophages, neutrophils and T cells into the inflamed intestine, result in greater activation and released of proinflammatory cytokines. Pathophysiologically, cytokines response to CD is TH1- and TH17 and UC are TH2 [30-32].

The activation of Protein kinases such as Janus-activated kinase (JAK), mitogen- activated Protein kinase (MAPK), phosphate-dylinosito-3-kinase (PI3K), transcription factors such as activation Protein-1 (AP-1), nuclear factor kappa B (NF- κ B) and hypoxia inducible factor-1 α (HIF-1 α), all members of single transducer and activator of transcription (STAT) leads to exacerbation of the UC [33-36]. This results in the inflammation to transfer from Mucosa and Submucosa to Muscularis propria and Serosa layers of tissues, which is transmural inflammation, so it is pathologically possible for UC to change into CD over the period of time. The difference between UC and CD is shown in **Table 1**.

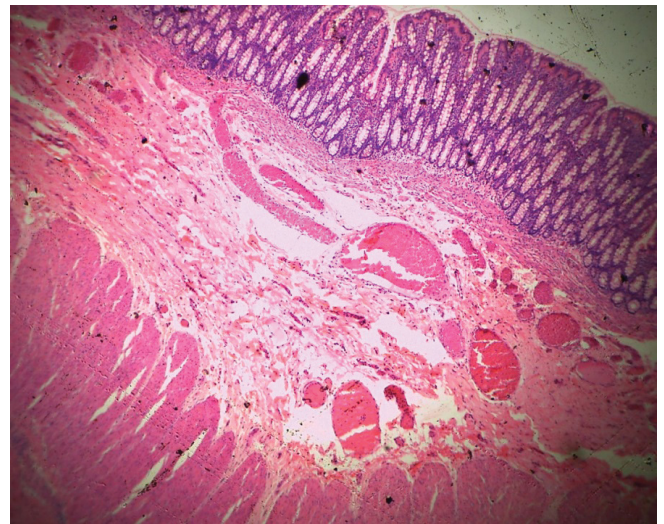


Figure 7 Normal colon showing four layers.

Table 1 Comparing ulcerative colitis and Crohn's disease.

Variables	Ulcerative Colitis	Crohn's Disease
Incidence	2.2-14.3 cases per 100,000 person-years (31)	3.1-14.6 cases per 100,000 person-years (31)
Age	15-30 years and 60-80 years (14)	15-30 years and 60-80 years (14)
Male: Female	1:1	1.1-1.8:1
Smoking	Prevent UC	Cause CD
Twins	Monozygotic=6% Di zygoti c=0%	Monozygotic=58% Di zygoti c=4%
Appendectomy	Protective	Non- protective
ORAL Contraceptive	No risk	Increase risk
Signs And Symptoms		
Stool	Gross blood with mucus frequently (32)	Gross blood with mucus occasionally
Pain	Sometimes (32)	Commonly
Fever	Only in severe case (32)	Commonly
Fistula	No (29)	Commonly
Tenesmus	Commonly	Less commonly
Weight Loss	Rarely	Often
ANCA	Positive	Negative
ASCA	Negative	Positive
Macroscopic		
Bowel Wall	Not Commonly thickened and narrowed	Commonly thickened and narrowed
Distribution	Continuous (33)	Not continuous
Side	Left	Right
Symmetry	Yes	No
Rectum	Commonly involved (33)	Rarely involved
Ileocecal Valve	Open	Stenosis
Terminal Ileitis	Backwash ileitis	String sign
Ulcers	No	Yes
Pseudo polyps	Yes	No
Microscopic		
Crypt Abscess	Yes	No
Mucosal/Submucosal Inflammation	Yes	No
Transmural Inflammation	Rarely	Yes (29)
Granulomas	No	Yes (30)
Fissure	No	Yes
Pathophysiology		
Cytokine associated with	Th2	Th 17 (30)
Treatment		
5-Asa	Effective (34)	Less effective
Antibiotics	Less effective (35)	Effective (36)
Surgery	No recurrence	Can be recurrent

Conclusion

In summary, here in this case report and literature review, we report the case of a patient who was operated for UC and accidentally we found that UC already progressed into CD in our post-colectomy microscopic finding. This case report and

literature review support the hypothesis that CD is a continuum of a UC.

Conflict of Interest

No financial tie or conflict of interest to declare.

References

- Mărginean CO, Meliș LE, Mocanu S, Mărginean MO (2017) Inflammatory bowel diseases: a burden in pediatrics: A case series and a review of the literature. *Medicine* 96.
- Podolsky DK (2002) Inflammatory bowel disease. *N Engl J Med* 347: 417-429.
- Larsen S, Bendtzen K, Nielsen OH (2010) Extraintestinal manifestations of inflammatory bowel disease: epidemiology, diagnosis, and management. *Ann Med* 42: 97-114.

- 4 Cosnes J, Gower–Rousseau C, Seksik P, Cortot A (2011) Epidemiology and natural history of inflammatory bowel diseases. *Gastroenterology* 140: 1785-1794.
- 5 Burisch J, Pedersen N, Čuković-Čavka S, Brinar M, Kaimakliotis I, et al. (2014) East–West gradient in the incidence of inflammatory bowel disease in Europe: the ECCO-EpiCom inception cohort. *Gut* 63: 588-597.
- 6 Leddin D, Tamim H, Levy AR (2014) Decreasing incidence of inflammatory bowel disease in eastern Canada: a population database study. *BMC Gastroenterology* 14: 140.
- 7 Molinie F, Gower–Rousseau C, Yzet T, Merle V, Grandbastien B, et al. (2004) Opposite evolution in incidence of Crohn's disease and ulcerative colitis in Northern France (1988 – 1999). *Gut* 53: 843-848.
- 8 Loftus CG, Loftus EV Jr, Harmsen WS, Zinsmeister AR, Tremaine WJ, et al. (2007) Update on the incidence and prevalence of Crohn's disease and ulcerative colitis in Olmsted County, Minnesota, 1940-2000. *Inflamm Bowel Dis* 13: 254-261.
- 9 Burisch J, Jess T, Martinato M, Lakatos PL, ECCO-EpiCo (2013) The burden of inflammatory bowel disease in Europe. *J Crohns Colitis*. 7: 322-337.
- 10 Prideaux L, Kamm MA, De Cruz PP, Chan FK, Ng SC (2012) Inflammatory bowel disease in Asia: a systematic review. *J Gastroenterol Hepatol* 27: 1266-1280.
- 11 Ouyang Q, Tandon R, Goh KL, Ooi CJ, Ogata H, et al. (2005) The emergence of inflammatory bowel disease in Asian pacific region. *Curr Opin Gastroenterol* 21: 408-413.
- 12 Lakatos PL (2006) Is the epidemiology of inflammatory bowel disease changing in Eastern Europe? *Scand J Gastroenterol* 41: 870-871.
- 13 Abraham C, Cho JH (2009) Inflammatory bowel disease. *N Engl J Med* 361: 2066-2078.
- 14 Ulcerative Colitis (2014) NIDDK.
- 15 Dai YC, Tang ZP, Ma GT, Gong YP, Liu W, et al. (2010) A review of Qingchang Shuan for treatment of ulcerative colitis. *J Tradit Chin Med* 30: 237-240.
- 16 Hendrickson BA, Gokhale R, Cho JH (2002) Clinical aspects and pathophysiology of inflammatory bowel disease. *Clin Microbiol Rev* 15:79-94.
- 17 Khor B, Gardet A, Xavier RJ (2011) Genetics and pathogenesis of inflammatory bowel disease. *Nature* 474: 307-317.
- 18 Langan RC, Gotsch PB, Krafczyk MA, Skillinge DD (2007) Ulcerative colitis: diagnosis and treatment. *Am Fam Physician* 76: 1323-1330.
- 19 Kornbluth A, Sachar DB (2010) Practice Parameters Committee of the American College of Gastroenterology. Ulcerative colitis practice guidelines in adults: American College of Gastroenterology, Practice Parameters Committee. *Am J Gastroenterol* 105: 501-523.
- 20 Shepherd NA (2002) Granulomas in the diagnosis of intestinal Crohn's disease: a myth exploded?. *Histopathology* 41: 166-168.
- 21 Mahadeva U, Martin JP, Patel NK, Price AB (2002) Granulomatous ulcerative colitis: A re-appraisal of the mucosal granuloma in the distinction of Crohn's disease from ulcerative colitis. *Histopathology* 41: 50-55.
- 22 Dwarakanath AD, Nash J, Rhodes JM (1994) Conversion from ulcerative colitis to Crohn's disease associated with corticosteroid treatment. *Gut* 35: 1141-1144.
- 23 Ke F, Yadav PK, Ju LZ (2012) Herbal medicine in the treatment of ulcerative colitis. *Saudi J Gastroenterol* 18: 3-10.
- 24 Sandborn WJ, Targan SR, Byers VS, Ruddy DA, Mu H, et al. (2013) *Andrographis paniculata* extract (HMPL- 004) for active ulcerative colitis. *Am J Gastroenterol* 108: 90-98.
- 25 Kent TH, Ammon RK, DenBesten L (1970) Differentiation of ulcerative colitis and regional enteritis of colon. *Arch Pathol* 89: 20-29.
- 26 Vester-Andersen MK, Prosborg MV, Jess T, Andersson M, Bengtsson BG, et al. (2014) Disease course and surgery rates in inflammatory bowel disease: a population-based, 7-year follow-up study in the era of immunomodulating therapy. *Am J Gastroenterol* 109: 705-714.
- 27 Lee HS, Choe J, Lee HJ, Hwang SW, Park SH, et al. (2016) Change in the diagnosis of inflammatory bowel disease: a hospital-based cohort study from Korea. *Intest Res* 14: 258-263.
- 28 Saboury B, Salavati A, Brothers A, Basu S, Kwee TC, et al. (2014) FDG PET/CT in Crohn's disease: correlation of quantitative FDG PET/CT parameters with clinical and endoscopic surrogate markers of disease activity. *Eur J Nucl Med Mol Imaging* 41: 605-614.
- 29 Hanauer SB, Sandborn W (2001) Management of Crohn's disease in adults. *Am J Gastroenterol* 96: 635-643.
- 30 Elson CO, Cong Y, Weaver CT, Schoeb TR, McClanahan TK, et al. (2007) Monoclonal anti-interleukin 23 reverses active colitis in a T cell-mediated model in mice. *Gastroenterol* 132: 2359-2370.
- 31 Loftus EV, Jr. (2004) Clinical epidemiology of inflammatory bowel disease: Incidence, prevalence, and environmental influences. *Gastroenterol* 126: 1504-1517.
- 32 Robert Löfberg (2010) internetmedicin.se > Inflammatorisk tarmsjukdom, kronisk, IBD.
- 33 Kornbluth A, Sachar DB (2004) Ulcerative colitis practice guidelines in adults (update): American College of Gastroenterology, Practice Parameters Committee. *Am J Gastroenterol* 99: 1371-1385.
- 34 Hagerstwon MD (2008) Lippincott Inflammatory bowel disease (IBD) in: Elizabeth D Agabegi; Agabegi, Steven S: Step-Up to Medicine (Step-Up Series). Williams & Wilkins, NY, USA. ISBN 0-7817-7153-6: 152–156.
- 35 Feller M, Huwiler K, Schoepfer A, Shang A, Furrer H, et al. (2010) Long-term antibiotic treatment for Crohn's disease: A systematic review and meta-analysis of placebo-controlled trials. *Clin Infect Dis* 50: 473-480.
- 36 Prantera C, Scribano ML (2009) Antibiotics and Ulcerative Colitis. In: Antibiotics and probiotics in inflammatory bowel disease: Why, when, and how. *Curr Opin Gastroenterol* 25: 329-333.