

DOI: 10.36648/2471-8041.6.3.149

The De Winter Dilemma: The Management and Outcome of a Patient with De Winter Electrocardiographic Pattern in the Pre-Hospital Setting

Ensaf Missaoui, Ben Cheikh Cherifa, Mahmoudi Ahmed, Mounir Naija* and Naoufel Chebili

Emergency Medical Service (SAMU 03), Sahloul University Hospital, Sousse, Tunisia

*Corresponding author: Mounir Naija, Emergency Medical Service (SAMU 03), Sahloul University Hospital, Sousse, Tunisia, Tel: + 21624497713, E-mail: mounirnaija@yahoo.fr

Received date: June 26, 2020; Accepted date: July 17, 2020; Published date: July 24, 2020

Citation: Missaoui E, Cherifa BC, Ahmed M, Naija M, Chebili N (2020) The De Winter Dilemma: The Management and Outcome of a Patient with De Winter Electrocardiographic Pattern in the Pre-Hospital Setting. Med Case Rep Vol.6 No.3:149.

Abstract

De Winter sign, first described by De Winter et al. in 2008, is an electrocardiographic (EKG) pattern associated with typical chest pain without classic ST-segment elevation that signifies total occlusion of the proximal left anterior descending coronary artery (LAD). In this case report we aim to highlight the dilemma of the use of thrombolytic therapy in patients with De Winter EKG pattern in the absence of immediate primary percutaneous coronary intervention (PPCI). A 66-year-old patient encountered the emergency department (ED) of a secondary care hospital for chest pain that began 30 minutes prior to his ED visit with more than 1 mm up-sloping ST depression with symmetric tall T in lead V3-V4-V5 and V6 characteristic of De Winter T-wave ECG pattern. The patient then presented a cardio-respiratory arrest with initial rhythm being read as pulseless ventricular tachycardia. He was resuscitated and received 3 shocks. The resuscitation was successful and EKG showed an ST segment elevation in the precordial leads. Thrombolytic therapy was administered and successful. Angiographic evidence of an occluded LAD was obtained later on. Although De Winter's pattern was proved to be a sign of critical occlusion of the proximal segment of LAD artery, there lacks proper guidelines on the management of this particular EKG sign. Moreover, thrombolytic therapy is still controversial in the presence of such a sign as current guidelines advocate against this therapy in the absence of STEMI. Our case report adds to the emergent cases of patients with EKG De Winter pattern having significant LAD occlusion that was successfully treated with thrombolytic agents.

Keywords: De Winter Sign; Emergency department; Thrombolysis; Proximal left anterior descending coronary artery

Upsloping ST segment depression >1 mm at the J-point in the precordial leads, tall, prominent, symmetric T waves in the precordial leads, absence of ST elevation in the precordial leads and ST segment elevation (0.5–1 mm) in aVR lead [1]. This pattern was found to be associated with acute complete occlusion of left anterior descending artery [2]. The prevalence of this sign noted in acute myocardial infarction was found to be 2% [3-5].

Despite the increasing influx of many case reports of patients presenting with De Winter's sign, followed by immediate cardiac catheterization revealing significant, acute occlusion of proximal LAD and treated with stents [6-9]. Recent guidelines by the European society of cardiology (ESC) and the American Heart Association did not suggest its management as STEMI equivalent. Moreover, these guidelines advocate against fibrinolytic therapy in the absence of STEMI.

In this case report, we aim to highlight the importance of recognition of De Winter's pattern and the dilemmatic question of its management in the absence of immediate primary percutaneous coronary intervention (PPCI).

Case Presentation

A 66-year-old man presented to the emergency department (ED) of secondary regional hospital with a crushing chest pain for 30 minutes before his ED's visit. He did not report shortness of breath or prior episodes of chest pain. He had no medical history of diabetes, smoking, previous stroke or myocardial infarction. Initial examination showed stable vitals: blood pressure (BP) was 120/70 mmHg, heart rate (HR) was 69 bpm, respiratory rate was 20 breaths pm, oxygen saturation (SpO₂) was 98% while patient was breathing ambient air and the cardiopulmonary examination was within normal limits. ECG showed a sinus rhythm of 60 bpm, >1 mm upsloping ST depression with symmetric tall T in lead V3-4-5-6 characteristic of De Winter T-wave ECG pattern (**Figure 1**) with ST-elevation of 1 mm in lead aVR (**Figure 2**).

Introduction

De Winter sign is an electrocardiography pattern first described by De Winter et al. in 2008. It is characterized by

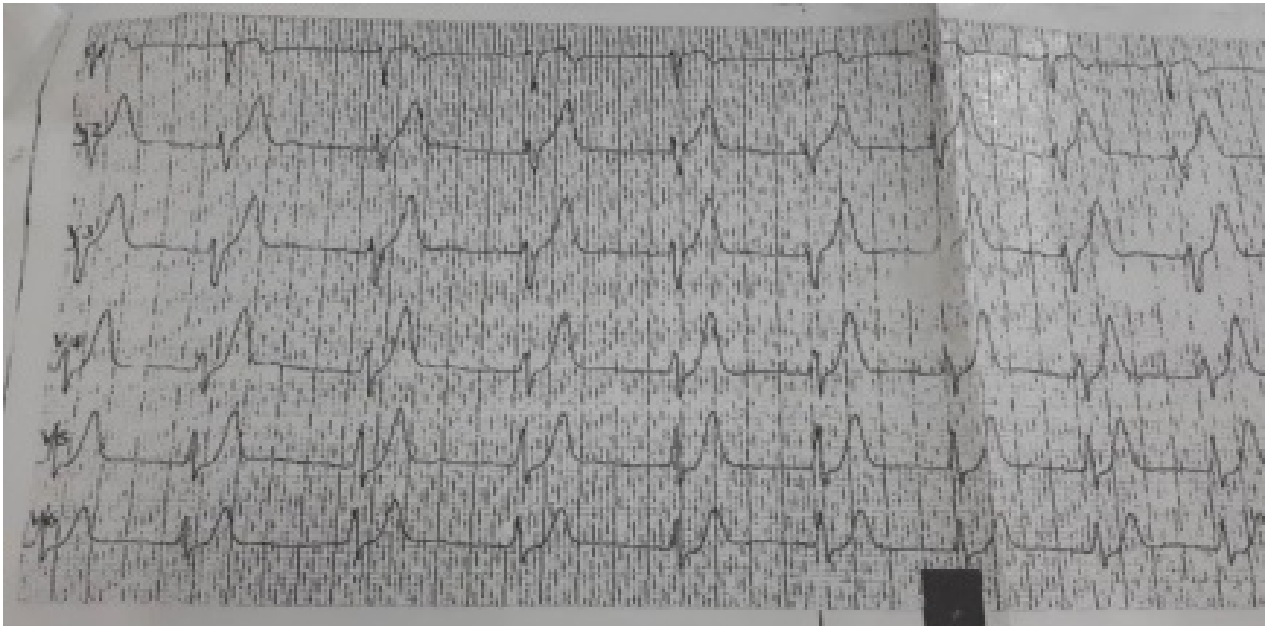


Figure 1: De Winter T-wave ECG pattern: >1 mm upsloping ST depression with symmetric tall T in lead V3-4-5-6.

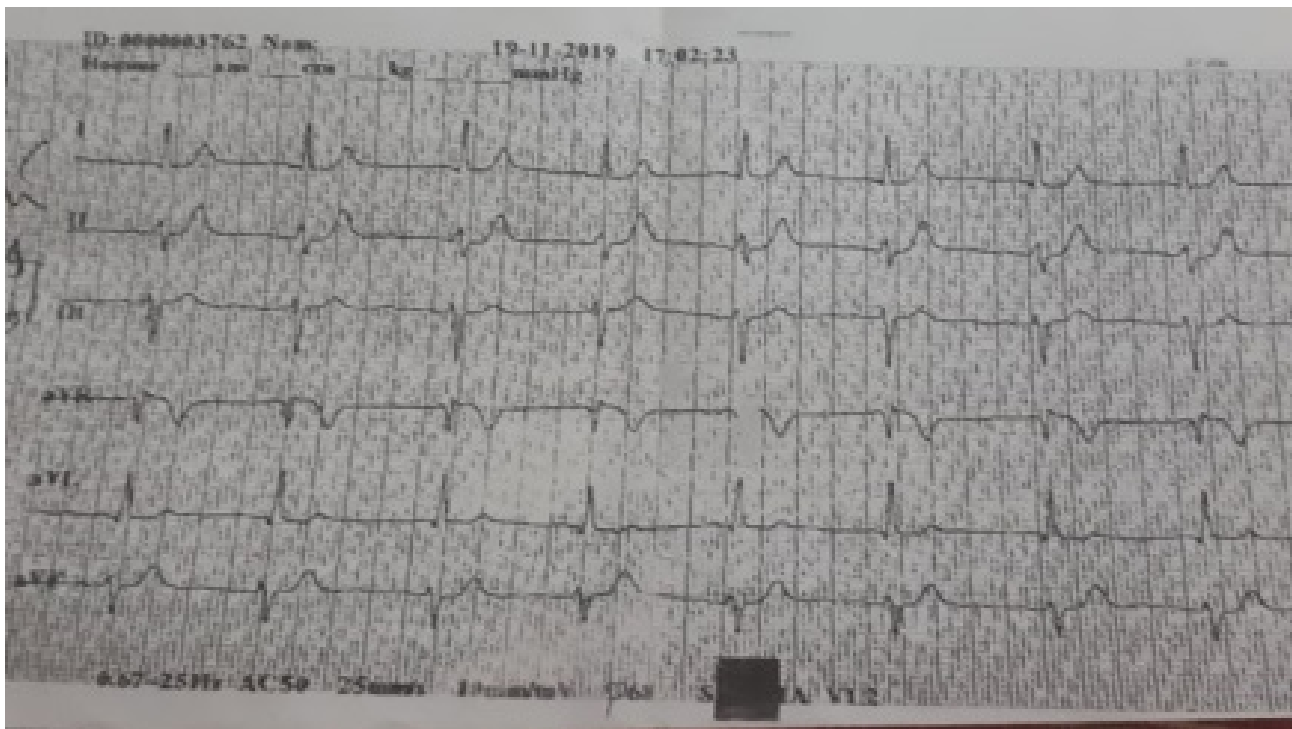


Figure 2: ST-elevation of 1 mm in lead aVR.

The patient was given dual antiplatelet therapy and anticoagulant. The emergency medical service (EMS) was needed to refer the patient to a hospital where interventional cardiology was available (the University hospital of Monastir). Before the EMS team's arrival, the patient presented a cardio-respiratory arrest and cardiopulmonary resuscitation (CPR) was initiated with initial rhythm being read as pulseless ventricular tachycardia. The resuscitation remained 6 minutes

during which the patient received three shocks. After the third shock, resuscitation was successful. Post resuscitation vitals were as follows: BP= 110/60 mmHg, HR= 66 bpm, RR=22 cpm, SaO₂= 95% (while patient was breathing ambient air). The patient was conscious but in pain. ECG showed irregular supraventricular activity at 66 bpm with ST-segment elevation in lead V1-2-3-4-5-6 of more than 2 mm with Q-waves developing in the same leads, consistent with acute STEMI

(Figure 3) and a concomitant ST segment depression of more than 0.5 mm in the leads D2, D3, aVF (Figure 4).

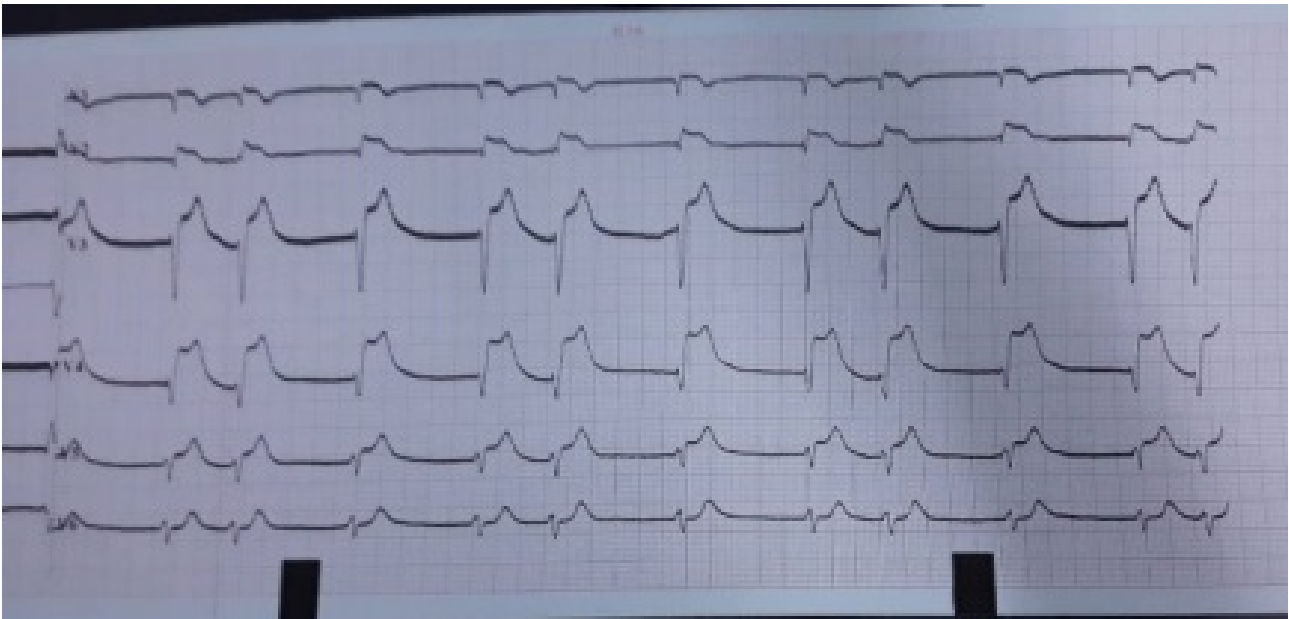

Figure 3: ST-segment elevation in lead V1-2-3-4-5-6 of more than 2 mm with Q-waves developing in the same leads.

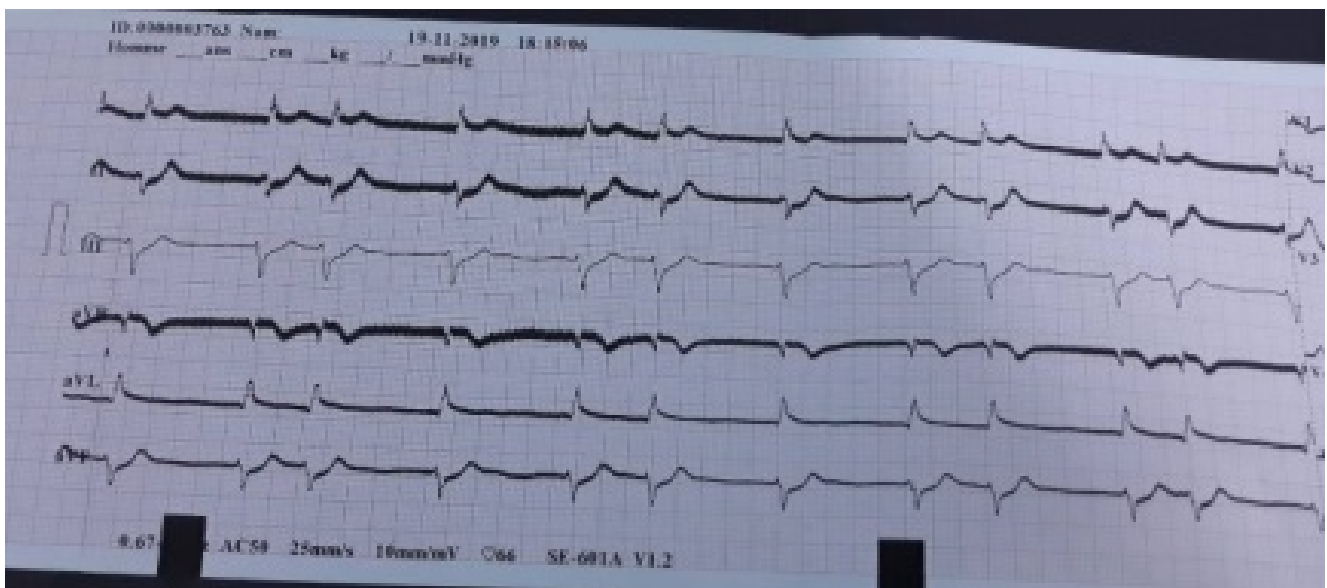


Figure 4: ST segment depression of more than 0.5 mm in the leads D2, D3, aVF.

The patient received thrombolytic therapy (tenecteplase) seen that chest pain was intense and persistent on the one hand and referral to a hospital with interventional cardiology facility (University Hospital of Monastir) outlasted the recommended delays on the other hand. The chest pain subsided and the patient was transported to the cardiology facility of Monastir by the Emergency Medical Services' (EMS) team. A coronary angiography was performed in the same day showing a critical occlusion of the LAD artery (TIMI flow grade 2) and a less severe occlusion of the circumflex artery (TIMI

flow grade 3). A successful stenting of the LAD artery was performed.

Discussion

Although current ESC's and AHA's guidelines do not classify the De Winter electrographic pattern as a STEMI equivalent, this sign, in the presence of ischemic chest pain should be recognized by physicians and should ideally be treated as

urgent STEMI, with catheter lab activation for coronary angiography and possible stenting.

In fact, this pattern was proven to be highly accurate in diagnosing anterior MI caused by acute proximal LAD occlusion as it had high positive predictive values of 95.2% (95% confidence interval: 76.2–99.9%), 100% (69.2–100.0%), and 100% (51.7–100%) for acute coronary occlusions in three diagnostic studies [10].

The exact electrophysiologic mechanisms involved in the observed ECG changes are unknown. According to current knowledge, this ECG pattern corresponds to a critical sub occlusion of LAD — with ST-segment elevation ultimately occurring as soon as the vessel is totally occluded.

The moderate ST-segment depression as well as the tall, peaked T waves is physiologically attributed to a—hypoxia driven—alteration in ATP-dependent potassium channels, resulting in a delay in repolarization in the subendocardial region, with a change in the transmembrane action potential shape [11].

We presented the case of a patient who presented to the ED with persistent severe crushing chest pain with an electrography not showing STEMI yet De Winter T wave pattern. We chose not to administer thrombolytic therapy initially because of the absence of guidelines that advocate towards the use of such therapy in the absence of persistent ST-segment elevation. Thus, we opted for dual antiplatelet therapy, anticoagulation and tried to refer the patient to a hospital with interventional cardiology facility.

What distinguishes this case is the occurrence of cardio respiratory arrest with pulseless ventricular tachycardia even in the absence of initial persistent ST segment elevation.

Eventually, the post resuscitation electrographic evolution into a persistent ST segment elevation in the precordial leads with persisting severe pain, helped us choosing thrombolytic therapy for the patient's management.

Similar circumstances were reported by an Indonesian team where the fibrinolysis of a patient with initial De Winter pattern was successful [12]. Other case reports were published by Oxford University Press supporting the efficacy of thrombolytic therapy using prourokinase in the management of patients with electrocardiographic De Winter pattern [13].

In the same perspective, Shergill et al. describes a case where a 34-year-old male smoker in India presenting with angina and EKG compatible with De Winter's sign being successfully thrombolysed with streptokinase with relief of symptoms and EKG returning to baseline. Thrombolysis was done because of the lack of availability of a cardiac catheterization lab at the facility and financial constraints of the patient [14].

The De Winter EKG pattern was also identified immediately after ventricular tachycardia cardiac arrest in a 33-year-old man by an Israeli emergency team [15]. Despite the increasing cases of successful thrombolysis in the presence of De Winter sign, there still are no clear guidelines in this matter. In

addition, current guidelines advocate against thrombolytic treatment in NSTEMI. However, the question still arises about fibrinolysis being an optional therapy in this context in the absence of immediate PPCI, which is the case in low-income countries.

Conclusion

De Winter syndrome is a condition associated with typical chest pain and a characteristic ECG pattern without classic ST segment elevation that is estimated to be present in about 2% of patients with acute anterior myocardial infarction. Up to this date, there still are no clear guidelines concerning the reperfusion therapy strategy in the presence of such severe syndrome, particularly in the lack of hospitals with interventional cardiology facilities, such is the case of most of low-income countries.

This calls for further multicentric randomized double blinded studies in this matter in order to answer the dilemmatic question of reperfusion therapy in the presence of De Winter pattern.

References

1. O'Gara PT, Kushner FG, Ascheim DD, Casey DE, Chung MK, et al. (2013) 2013 ACCF/AHA guideline for the management of ST-elevation myocardial infarction: executive summary: a report of the American College of Cardiology Foundation/American Heart Association Task Force on Practice Guidelines. *J Am Coll Cardiol* 61: 485-510.
2. Nikus KC, Eskola MJ (2008) Electrocardiogram patterns in acute left main coronary artery occlusion. *J Electrocardiol* 4: 626-629.
3. De Winter RJ, Verouden NJ, Wellens HJ, Wilde AA (2008) A new ECG sign of proximal LAD occlusion. *N Engl J Med* 359: 2071-2073.
4. Verouden NJ, Koch KT, Peters RJ, Henriques JP, Baan J, et al. (2009) Persistent precordial "hyperacute" T-waves signify proximal left anterior descending artery occlusion. *Heart* 95: 1701-1706.
5. De Winter RW, Adams R, Amoroso G, Appelman Y, Ten Brinke L, et al. (2019) Prevalence of junctional ST-depression with tall symmetrical T-waves in a pre-hospital field triage system for STEMI patients. *J Electrocardiol* 52: 1-5.
6. Abbasian A, Baratloo A, Abbasi N (2019) de-Winter syndrome; ST-T changes equivalent of acute myocardial infarction. *Vis J Emerg Med* 15: 100571.
7. Qayyum H, Hemaya S, Squires J, Adam Z (2018) Recognising the De Winter ECG pattern—A time critical electrocardiographic diagnosis in the Emergency Department. *J Electrocardiology* 51: 392-395.
8. De Winter RW, Adams R, Verouden NJ, De Winter RJ (2016) Precordial junctional ST-segment depression with tall symmetric T-waves signifying proximal LAD occlusion, case reports of STEMI equivalence. *J Electrocardiol* 49: 76-80.
9. Yang W, Liu H, Zhu M, Song Z (2017) The De Winter electrocardiographic pattern of proximal left anterior descending occlusion. *Am J Emerg Med* 35: 937-e1.

10. Morris NP, Body R (2017) The De Winter ECG pattern: morphology and accuracy for diagnosing acute coronary occlusion: A systematic review. *Eur J Emerg Med* 24: 236-242.
11. Tzimas G, Antiochos P, Monney P, Eeckhout E, Meier D, et al. (2019) Atypical electrocardiographic presentations in need of primary percutaneous coronary intervention. *Am J Cardiol* 124: 1305-1314.
12. Pranata R, Huang I, Damay V (2018) Should De Winter T-wave electrocardiography pattern be treated as ST-segment elevation myocardial infarction equivalent with consequent reperfusion? A dilemmatic experience in rural area of Indonesia. *Case Rep Cardiol* 2018.
13. Rao MY, Wang YL, Zhang GR, Zhang Y, Liu T, et al. (2018) Thrombolytic therapy to the patients with De Winter electrocardiographic pattern, is it right?. *QJM: Int J Med* 111: 125-127.
14. Shergill GS, Singh A, Meena NK (2017) De Winters pattern: Spotted and successfully thrombolysed with streptokinase. *Heart India* 5: 157.
15. Carr MJ, O'Shea JT, Hinfey PB (2016) Identification of the STEMI-equivalent De Winter electrocardiogram pattern after ventricular fibrillation cardiac arrest: A case report. *J Emerg Med* 50: 875-880.