

DOI: 10.36648/2471-8041.6.2.145

Successful Surgical Treatment of a Complicated and Infected right Thumb Wound without Antibiotics: A Case Report

Stanko J. Baco*

General Hospital, Prijedor, Bosnia and Herzegovina

*Corresponding author: Dr. Stanko. J. Baco, General Hospital, Prijedor, Bosnia and Herzegovina, Tel:+38766630905, E-mail: sbaco3@gmail.com

Received date: May 15, 2020; Accepted date: July 01, 2020; Published date: July 07, 2020

Citation: Baco SJ (2020) Successful Surgical Treatment of a Complicated and Infected right Thumb Wound without Antibiotics: A Case Report. Med Case Rep Vol.6 No.3:145.

Abstract

This case is about a 23-year-old male patient with right thumb injured accidentally by combine harvester is undergone surgical treatment by reducing use of antibiotics. We support the current efforts to reduce antibiotic use in the face of rising threat of antimicrobial resistance, because we have concern that antibiotics are becoming routine.

Keywords: Antibiotics; Surgery; Thumb

Introduction

All over the world, visits to the emergency departments because of skin and soft-tissue infections are increasing yearly. Reasons for that are increased incidence of abscesses and bacterial resistance [1,2]. The primary treatment of cutaneous abscess is drainage alone. Whether adjunctive antibiotics improve the outcome or just cause more cost and side effects, is unclear but we are afraid that antibiotics are becoming routine [3].

Case Report

In early October a 23-year-old student presented to our surgical outpatient clinic with a two week old infected wound on his right thumb for a control examination. The injury was caused by a combine harvester, during work in the fields.

Initially, the lacer contusive wound was treated at the emergency surgical clinic of our hospital. Sanatio per primam intentional - the patient received 8-10 stitches, two antibiotics, analgesics if needed, information to check his tetanus vaccine status in case a booster was needed. He was instructed to report to his family doctor every 48 hours for wound control and cleansing (as per SP - standard procedure) and to a surgeon for control after 10 days. He did everything as advised.

After ten days he was seen by a surgeon and was told that the stitches wouldn't be removed, because the wound was still leaking'. Instead, he should report for a control again after another 3 days.

Two weeks after the injury (**Figure 1**), the patient, a healthy young student with no history of any chronic diseases, came to control for the second time.

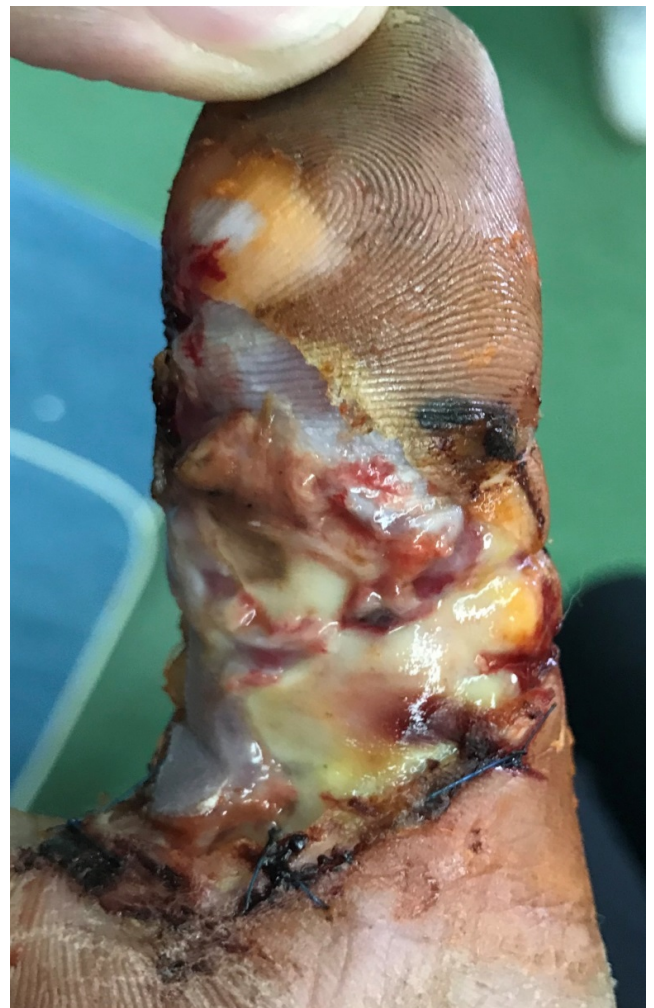

Figure 1: At the patient's second control, 2 weeks after the injury.

At that time of (patient's second control) presentation the finger was swollen and the wound on the finger was covered with a yellowish membrane. After we took the membrane off, we discovered that the finger was in a disastrous state: it was

swollen, the skin was decolorated and partially macerated; the soft tissues were necrotic, covered with pus and the wound smelled badly. There was no evidence of systemic toxicity. Luckily the swelling had not spread on the hand or forearm, the extent of the infection was limited only to the thumb. At this moment we thought about allied tendynovitis and osteomyelitis as a complication? We also thought - what to do next? Should we make an X-ray of the finger?

Should we take a bacterial wound culture and Gram stain? Or should we admit the patient to the hospital gave him IV antibiotics, analgesics and do the debridement or even amputation? Or will all of it and in the same order be necessary? The surgical intervention had been done – urgently – debridement to the healthy, bleeding tissue, without anesthesia (**Figure 2**).

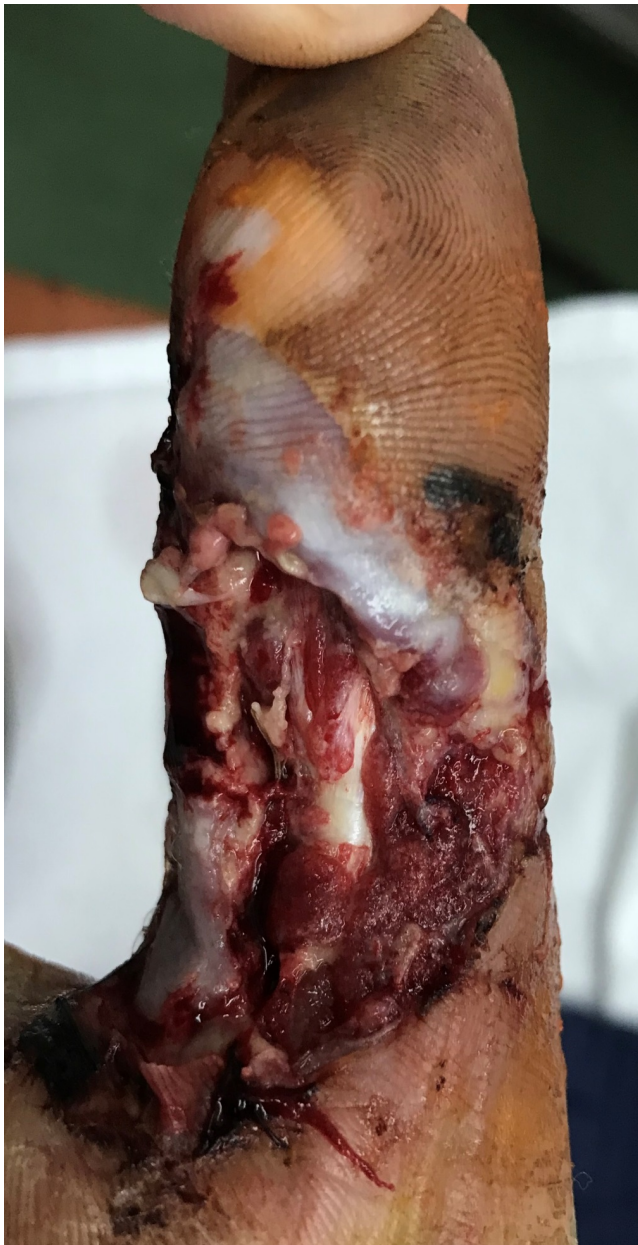

Figure 2: After debridement.

Post-operatively, the patient had not received any antibiotics - no additional empiric antibiotic therapy. The patient was sent home with the advice that the wound should be cleaned at least twice a day. Re-inspection was scheduled for 72 hours.

Three days after the first, followed the second debridement (**Figure 3**) and weeks after second debridement (**Figure 4**). The patient did well and has not had any complications (i.e., contractures) (**Figure 5**).

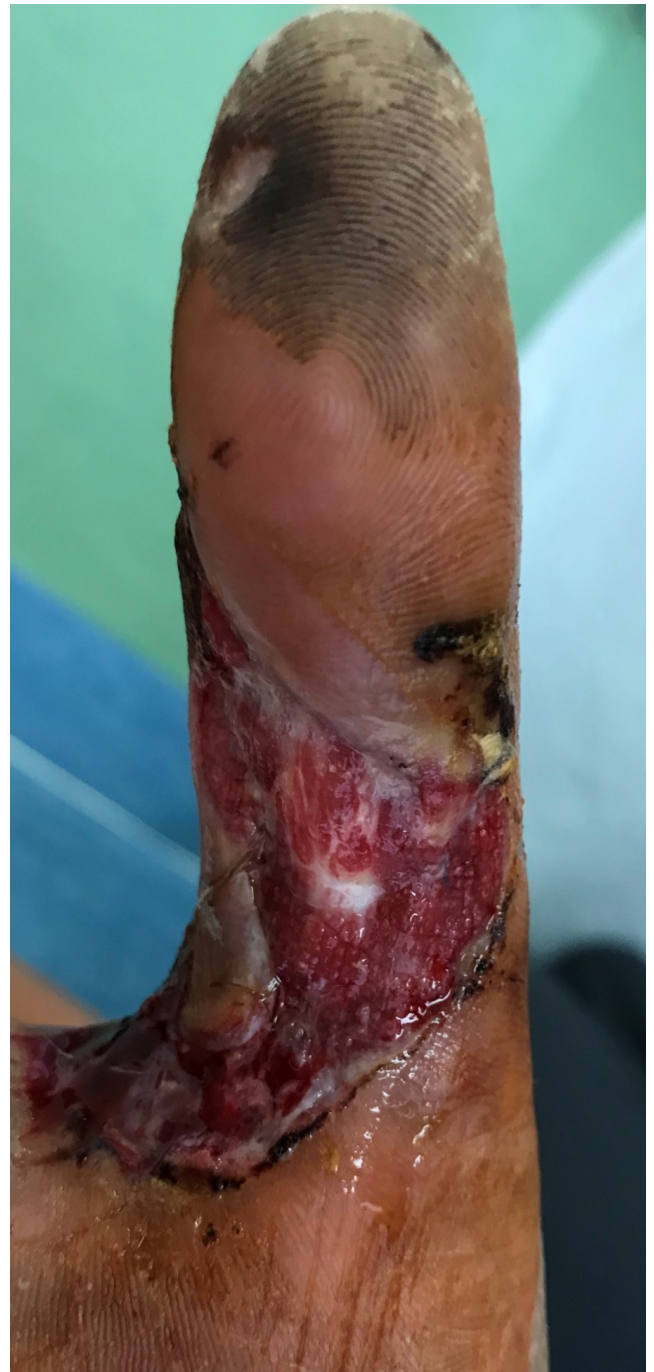

Figure 3: After the second debridement.

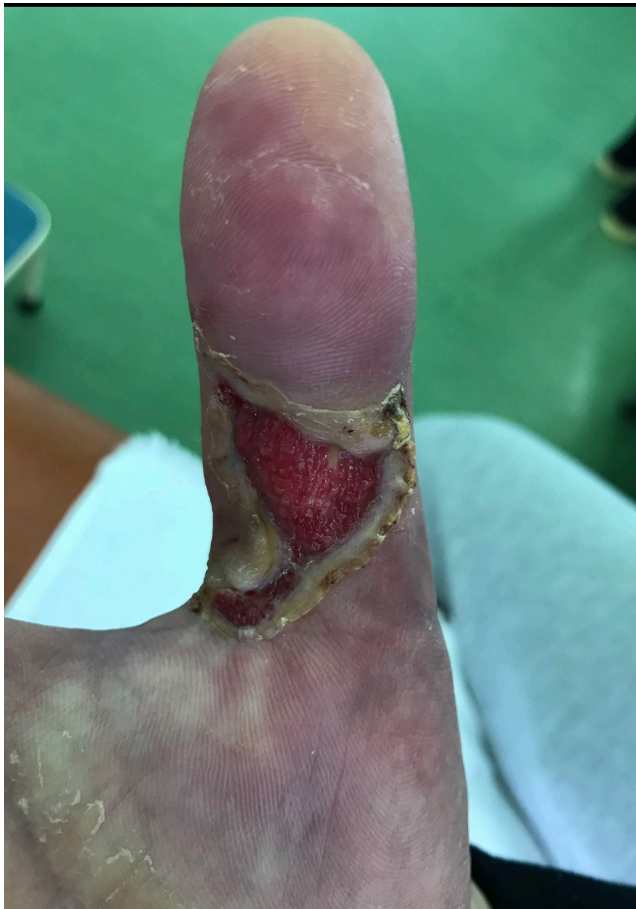

Figure 4: 2 Weeks after second debridement.

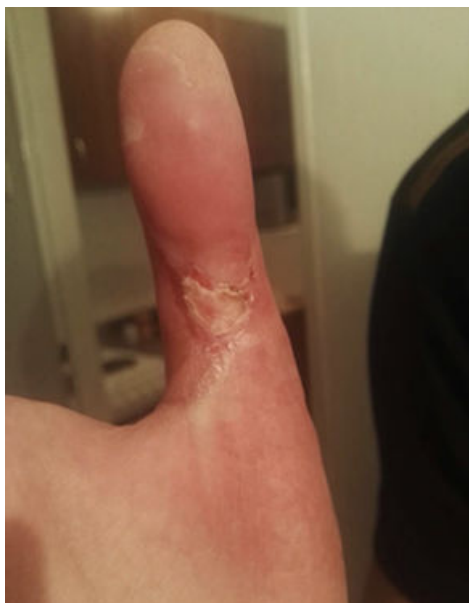

Figure 5: After 3 weeks treatment.

Discussion

Practice guidelines for abscess treatment state that drainage is sufficient for most of the patients and recommend adjuvant antibiotics for patients who have certain clinical characteristics like systemic inflammatory response syndrome, diabetes, infected site with diameter of more than 5 cm, surrounding cellulitis etc. [4,5].

Other problems and what should have been done better in this case were:

- The interval between the specialist's follow-up exam was set for too long (10 days) – it should have been 1 to 3 days
- The infection was not detected on time by the family doctor
- The wound had not been adequately cleaned? (- just an assumption)
- The surgeon had not recognized the infection and its severity on time.

No X-rays of the finger had been done because we thought we would decide after a clinical examination if it was necessary. Wound culture hadn't been taken because an empiric antibiotic therapy was not initiated, a poly-microbial culture would have come back, it would last a couple of days to get the results and an antibiogram would not be of much use for us, because the infection would already be under control). The patient was not admitted to the hospital because we thought an adequate source control and drainage in a young patient without any chronic diseases should be enough.

Treatments of SSTI over the world

This map is showing that all over the World, the incision and drainage alone is a praxis that is practiced by less than one third of surgeons, and that antibiotics, despite a lot of studies showing that there is no clear evidence to support the use of antibiotics in treating uncomplicated SSTIs, are widely prescribed in treatment of SSTI (Figure 6).

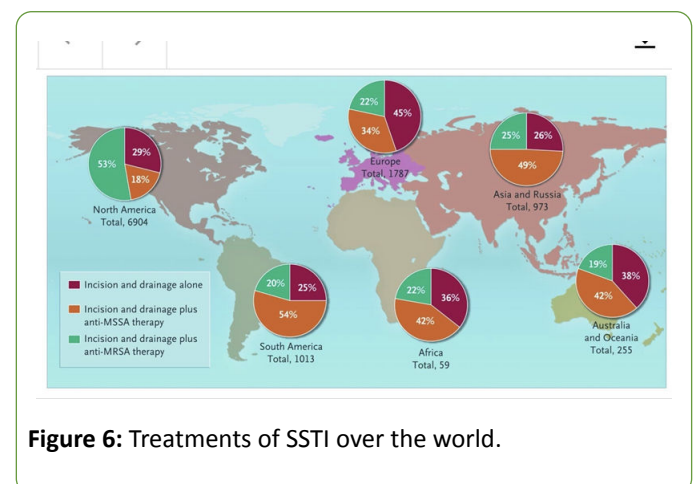


Figure 6: Treatments of SSTI over the world.

Conclusion

Early recognition of a wound infection, adequate surgical treatment and wound care, without use of antibiotics, should

be enough in healthy patients, even with complications like this one.

We support the current efforts to reduce antibiotic use in the face of rising threat of antimicrobial resistance, because we have concern that antibiotics are becoming routine. If the antibiotics are used, than after drainage – adequate source control and that would shorten the course (to maximum 3 days), provide equivalent clinical benefit, reduce the risk of adverse effects and decrease the pressure of development of resistance.

References

1. Chambers HF, Moellering RC Jr, Kamitsuka P (2008) Management of skin and soft-tissue infection. *N Engl J Med* 359: 1063-1067.
2. Hersh AL, Chambers HF, Maselli JH, Gonzales R (2008) National trends in ambulatory visits and antibiotic prescribing for skin and soft-tissue infections. *Arch Intern Med* 168: 1585-1591.
3. Fahimi J, Singh A, Frazee BW (2015) The role of adjunctive antibiotics in the treatment of skin and soft tissue abscesses: a systematic review and meta-analysis. *Canadian Journal of Emergency Medicine* 17: 420-432.
4. Liu C, Bayer A, Cosgrove SE, Daum RS, Fridkin SK, et al. (2011) Clinical practice guidelines by the infectious diseases society of america for the treatment of methicillin-resistant *Staphylococcus aureus* infections in adults and children: An executive summary. *Clin Infect Dis* 52: 285-292.
5. Talan DA, Mower WR, Krishnadasan A, Abrahamian FM, Lovecchio F, et al. (2016) Trimethoprim–sulfamethoxazole versus placebo for uncomplicated skin abscess. *N Engl J Med* 374: 823-832.