

DOI: 10.36648/2471-8041.6.3.148

Silk Suture Causing Late Post-Cholecystectomy Obstructive Jaundice: A Case Report

Mohamed Adel El-Basiony^{1,2*}, Ramy Hassan Agwa^{1,3}, Reham Soliman^{2,4}, and Gamal Shiha^{1,2}

¹Hepatology and Gastroenterology Unit, Department of Internal Medicine, Faculty of Medicine, Mansoura University, Egypt

²Egyptian Liver Research Institute and Hospital (ELRIAH), Sherbin, El-Mansoura, Egypt

³Department of Internal Medicine, Albaha University, Kingdom of Saudi Arabia

⁴Department of Tropical Medicine, Faculty of Medicine, Port Said University, Port Said, Egypt

*Corresponding author: Mohamed Adel El-Basiony, Hepatology and Gastroenterology Unit, Department of Internal Medicine, Faculty of Medicine, Mansoura University, Egypt, Tel: + 201008060797, E-mail: elbasiony.m@gmail.com

Received date: June 17, 2020; Accepted date: July 16, 2020; Published date: July 23, 2020

Citation: Elbasiony MA, Agwa RH, Soliman R, Shiha G (2020) Silk Suture Causing Late Post-Cholecystectomy Obstructive Jaundice: A Case Report. Med Case Rep Vol.6 No.3:148.

Abstract

Obstructive jaundice is usually caused by stones or malignant process. Post-surgical foreign bodies causing obstructive jaundice is a matter of rarest rarity and in most cases it leads to stone formation. A case with history of open cholecystectomy 2 years ago presented with obstructive jaundice that appeared initially using MRCP to be due to biliary stones. During ERCP; a foreign body was found in the common bile duct distal end. The foreign body was extracted and found to be a silk suture that appears to had found its way to the biliary tree lately after the initial surgery and led to obstructive jaundice. Post-open cholecystectomy biliary obstruction may be caused by surgical foreign bodies including suture materials without stone formation and it may have a late presentation.

Keywords: Obstructive jaundice; Silk suture; ERCP

Introduction

A foreign body causing obstructive jaundice is a rare presentation and is shown in some case reports. Sporadic reports have been published due to parasites, fish bones, fragments of T-tubes or other rubber objects, shrapnel, metal clips, migrated stents, surgical gauze and non-absorbable suture material, which serve as a nucleus for formation of stones or molds in the bile duct [1-4]. The retrieval of post-surgical biliary tree foreign bodies was reported in some cases like in post liver transplantation with extraction of elongated biliary mold [5], post simple open cholecystectomy with extraction of surgical gauze [1], post-cholecystectomy and drainage for hydatid disease of the liver with textiloma mimicking a common bile duct (CBD) stone [2] and endoclip migration into common bile duct after laparoscopic

cholecystectomy causing common bile duct stone formation [6].

Case Description

A 35-years Egyptian woman presented with abdominal pain and obstructive jaundice that appeared 10 days ago. Abdominal ultrasonography revealed dilated CBD and intrahepatic biliary radicles (IHBRs) and absent gall bladder (history of open cholecystectomy 2 years ago). Laboratory investigations revealed elevated serum bilirubin with cholestatic pattern (total serum bilirubin 5.2/direct serum bilirubin 3.9), ALT 98, alkaline phosphatase 300 IU, hemoglobin 12 gm/dl, platelets count 152 k/dl, WBCs 11.4 k/dl, serum creatinine 1 mg/dl, albumin 3.8 gm/dl HCV antibody negative, HBs antigen negative and HIV antibody negative. Magnetic resonance cholangiogram revealed dilated CBD with 2 signal void stones at distal end the larger is 5 mm and dilated IHBRs. No relevant medical or family history found. Open cholecystectomy was done 2 years ago without apparent problems.

Endoscopic retrograde cholangiopancreatography (ERCP) was done 1 day later. The duodenoscopic view revealed papilla with protruding dark foreign body that appeared initially as a papilla in delivery of a stone (**Figure 1**). Selective CBD cannulation using sphincterotome was done and a cholangiogram revealed dilated CBD and IHBRs with filling defects in the lower end of CBD. Balloon sweeping led to extraction of elongated foreign body (**Figure 2**) out of CBD through the papilla, appearing as an Ascaris worm at the first look. A foreign body forceps was used to catch the foreign body then extrusion of the scope (not to in lodge the foreign body in the scope channel). Examination of the foreign body revealed that it is a 4 cm long surgical silk suturing material with knots (**Figure 3**).

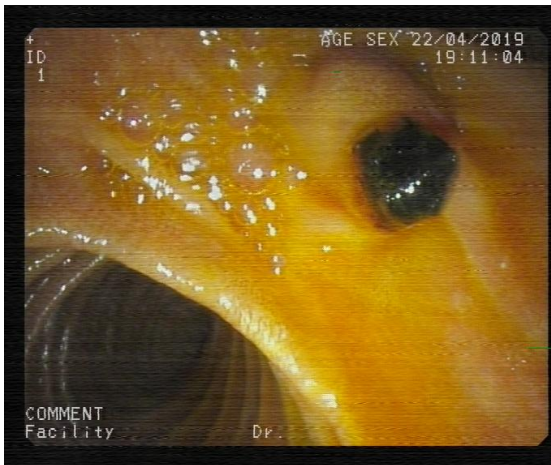

Figure 1: Papilla with protruding dark foreign body.

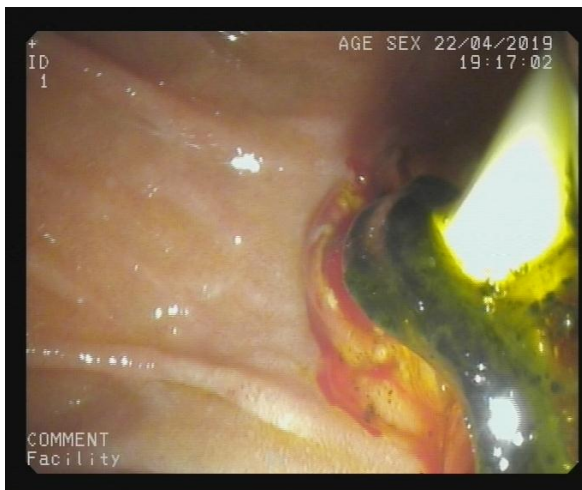

Figure 2: Extraction of elongated foreign body out of the CBD using Balloon.

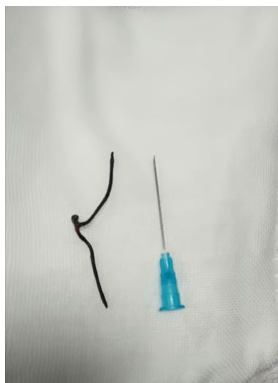


Figure 3: Surgical silk suturing material with knot.

normalization of serum bilirubin (0.9 mg/dl) and liver enzymes.

Discussion

Our case presented with the picture of extrahepatic biliary obstruction by, what appeared initially to be a primary CBD stone that is formed 2 years after open cholecystectomy. The incidence of recurrent cholelithiasis after cholecystectomy is estimated to be 2–10% [1]. MRCP revealed a lower end CBD filling defect consistent with CBD stone. At ERCP the story showed its real face and it was a different scenario. Endoscopic view of the papilla revealed a protruding foreign body through the papilla. After selective CBD cannulation, cholangiogram revealed dilated CBD and IHBRs with lower end CBD filling defect. Minor sphincterotomy followed by balloon sweeping with showed an elongated cord like foreign body extracted out of the CBD. Extraction of this cordy foreign body out of the patient's body and on examination of the cordy foreign body it was confirmed to be a silk suture with knot with no evidence of any biliary stones. To the best of our knowledge, this is the first case to report a biliary silk suture leading to obstructive jaundice without stone formation. Complete clinical improvement was done after removal of the silk suture foreign body.

Gallstones disease is common and cholecystectomy is the treatment of choice for symptomatic disease. Cholecystectomy is one of the most common operations in clinical practice, and in the United States, over half a million procedures are carried out annually [7]. Obstructive jaundice following cholecystectomy (either open or laparoscopic) has been reported by many mechanism including biliary tree injury, ligation, clipping and ischemia [8].

Some case reports and case series documented other methods of biliary tree injury and/or obstruction following cholecystectomy leading to obstructive jaundice. Mechanisms contributing to stone formation include presence of clip as nidus, lithogenic bile, and bacterobilia [9].

Stones may also be formed around a nidus of suture materials as reported by Kim et al. [10] a case in which suture material that had migrated from a previous cholecystectomy site into the CBD, probably served as a nidus for common bile duct stone formation. Silk, chromic catgut, parasites, and other foreign bodies are known to form occasionally such niduses in the CBD [11-13]. Surgical clips are reported to be the most commonly reported FBs that induce iatrogenic biliary stones. The underlying mechanism of the way in which FBs-including surgical clips and suture materials (silk in our case) end up in the biliary system is unknown. Bile-duct injuries, inappropriate clip placements, sub-clinical bile leak, and infections also have been postulated to contribute to clip migration [14].

Surgical gauze was reported as a cause of obstructive jaundice even without stone formation. Ciopletta et al. [1] reported successful removal by endoscopy of a surgical gauze seven years after a simple cholecystectomy.

In the follow up of the patient 1 week later revealed general improvement with absence of abdominal pain and

Conclusion

In the current case, the mechanism of silk suture introduction inside the biliary tree is unclear. Direct introduction during surgery, penetrating injuries, entero-bilio reflux, or erosions with eventual migration into the biliary system have been postulated. Post-open cholecystectomy biliary obstruction may be caused by surgical foreign bodies including suture materials without stone formation and it may have a late presentation.

References

1. Cipolletta L, Bianco MA, Rotondano G, Prisco A, Catalano M, et al. (1997) Endoscopic retrieval of a surgical gauze from the common bile duct. *Ital J Gastroenterol Hepatol* 29: 58.
2. Cimsit B, Keskin M, Ozden I, Alper A (2006) Obstructive jaundice due to a textiloma mimicking a common bile duct stone. *J Hepatobiliary Pancreat Surg* 13: 172-173.
3. Bhandari V, Singh M, Vyas HG, Sharma N, Chejara R (2011) Diagnostic dilemma in an unusual case of common bile duct obstruction. *Gut Liver* 5: 245.
4. Martos M, Cosme A, Bujanda L, Múgica F, Martín L, et al. (2011) Ictericia obstructiva por molde biliar debido a cuerpo extraño. *Rev Esp Enferm Dig* 103: 36-37.
5. Giestas S, Mendes S, Gomes D, Sofia C (2016) Obstructive jaundice due to foreign body in the bile duct: An unusual finding. *GE Port J Gastroenterol* 23: 228.
6. Sormaz IC, Keskin M, Sönmez RE, Soytaş Y, Tekant Y, et al. (2015) Obstructive jaundice secondary to endoclip migration into common bile duct after laparoscopic cholecystectomy. *Minerva Chir* 70: 381.
7. Ellison EC, Carey LC, Baker JR, Fishcer JE (2001) Cholecystectomy, cholecystostomy, and intraoperative evaluation of the biliary tree. *Mastery of Surgery*. (4th edn). Philadelphia: Lippincott Williams & Wilkins.
8. Buanes T, Mjåland O (1996) Complications in laparoscopic and open cholecystectomy: a prospective comparative trial. *Surg Laparosc Endosc* 6: 266-272.
9. Chong VH, Chong CF (2010) Biliary complications secondary to post-cholecystectomy clip migration: A review of 69 cases. *J Gastrointest Surg* 14: 688-696.
10. Kim KH, Jang BI, Kim TN (2007) A common bile duct stone formed by suture material after open cholecystectomy. *Korean J Intern Med* 22: 279-282.
11. Sigler L, Sahler CO (1996) Silk: The nidus of a common bile duct calculus. *Surgery* 65: 276-279.
12. Fink DL, Budd DC (1983) Chromic suture material as a nidus for common duct stone formation. *Int Surg* 68: 151-152.
13. Lewis JW, Urdaneta LF (1981) Stone formation on silk suture after cholecochoduodenostomy. *South Med J* 74: 1280-1281.
14. Chong VH (2005) Iatrogenic biliary stone. *Surg Technol Int* 14: 147-155.