

Limitations of Analgesic Treatment in a Severe Sickle Cell Painful Vaso-Occlusive Crisis Complicated or Associated With Focal Involvement - About Two Cases

**Stéphanie Ngimbi Luntadila^{1,2,3},
Valentin Ngwamah Mukeba^{3,4},
Daniel Mwamba^{5*},
Sandra Tshiswaka Mbuyi^{1,2},
Paul Boma Muteb^{3,4},
Jules Panda Mulefu^{4,6},
Stanislas Wembonyama¹,
and Oscar Luboya Numbi¹**

Abstract

Painful vaso-occlusive crises constitute the main manifestation of sickle cell anemia diseases. Occurring in various locations, their frequency, intensity, and duration are variable for each patient. Relieving the resulting pain is an emergency, but this must take into account the underlying factors or pathologies involved in their occurrence in order to adapt the treatment and obtain an optimal result. This study reports two cases which highlight the complexity of the management of a vaso-occlusive crisis caused by pathology likely to mimic an event purely related to sickle cell anemia.

Keywords: Sickle cell anemia; Pain; Emergency

Received: September 13, 2020; **Accepted:** December 18, 2020; **Published:** December 28, 2020

Introduction

Life of most sickle cell patients is punctuated by recurrent hyperalgesic vaso-occlusive crisis (VOC). Appropriate management of each episode is essential to improve the quality of life of these patients [1]. Although, several cellular, biological and psychological mechanisms can trigger the vaso-occlusive crisis [2], environmental factors, such as climate, and localized pathology can maintain or aggravate the pain therefore complicating its management. Between December 2017 and February 2019, a clinical study was conducted in Lubumbashi, in DRC to assess the efficacy and tolerance of vascular therapy with electrical stimulation in the treatment of painful sickle cell vaso-occlusive crises. This is the VEST-RDC-01-2017 project. We report here, two cases from this study which highlight the difficulty of treating a painful vaso-occlusive crisis in the context of two underlying pathologies, aseptic osteonecrosis of the femoral head and osteomyelitis.

Case Report

Clinical case 1

A 13-year-old Male T.J., who weighs 43 kg, consulted for severe backache that started about 7 hours before seeking medical attention. The history revealed that he has been suffering from an

aseptic osteonecrosis of femoral head for the past 2 years (FICAT score stage II). On physical examination, we noted tenderness along the dorso-lumbar spine (D9-L5) as well as a limitation of amplitude and movement of the left hip with abduction at 25 degrees, adduction at 20 degrees, and an external rotation of the

- 1 University of Lubumbashi, Department of Pediatrics, Zambia
- 2 Jason Sendwe Provincial General Reference Hospital, Pediatrics Service, Zambia
- 3 SS Assistance, NPO, Zambia
- 4 Health Sciences Research Institute, Zambia
- 5 Centre for Infectious Diseases Research in Zambia (CIRDZ), Zambia
- 6 University of Lubumbashi, Department of Surgery, Zambia

*Corresponding author: Daniel Mwamba

✉ mwambalonga@gmail.com

CIDRZ Head Office, Plot 34620, Off Alick Nkhata Road, Mass Media, Lusaka, Zambia, P.O. Box 34681.

Tel: +260978625288

Citation: Luntadila SN, Mukeba VN, Mwamba D, Mbuyi ST, Muteb PB, Mulefu JP, et al. (2021) Limitations of Analgesic Treatment in a Severe Sickle Cell Painful Vaso-Occlusive Crisis Complicated or Associated With Focal Involvement - About Two Cases. Med Case Rep Vol.5 No.6:161

hip at 30 degrees. The intensity of pain was estimated at 10 by Visual Analog Scale (VAS).

The blood test done reported: Hb: 7.7 g/dL, Platelets: 528,000/mm³, ESR: 20 mm/h, CRP: 36.47 mg%, WBC: 15,600 cells/mm³, LDH: 827.1 IU/l. Radiography of the pelvis and hip showed osteophytes and that of the dorso lumbar spine revealed sign of osteonecrosis of the vertebrae L1-L5. Upon admission, 4.5 mg of intravenous morphine and 1 g of Perfalgan® infusion was initiated combined with electrical stimulation therapy using the DIAVEIN® device for 4 hours. Morphine bolus was repeated 12 hours later without obtaining pain sedation; therefore 44 mg of morphine in continuous intravenous infusion in a 0.9% saline solution was started. A second session of electrical stimulation was conducted 24 hours later. After 50 hours, we noted a persistence of pain at VAS 8 and a partial exchange transfusion was carried out.

At 72 hours, 22 hours after the partial exchange transfusion and analgesic treatment, VAS was still at 8. We had initiated a third session with the DIAVEIN® device; 4 hours after the electrical stimulation, VAS increased to 4, but any mobilization of the patient was exacerbating the pain. At the 144th hour, the orthopedic surgeon performed bilateral fodder of the femoral head. When the patient woke up there was no pain and at the 24th hour post-operative VAS remained at - 0 until the 5th day post operation when the patient was discharged (Figure 1).

Clinical case 2

A female 5-year-old K.J was admitted to the VEST-DRC project for severe VOC crisis located in the right upper limb with VAS at 7 for almost a week. 10 hours after the initiation of analgesic treatment, it was noted a reduction in acute pain. At 24 h hour, we noted a resurgence of pain with VAS at 6; the pain was described as circumferential upstream and downstream the right

elbow with mild localized warmth. The blood tests done showed: Hb: 7.2 g/dL, Platelets: 405,000/mm³, ESR: 60 mm/h, CRP: 100.43 mg%, GB: 15,000 mm³, FL: N5 6.4% L 39.9% M × 3.7%. Standards antero posterior and lateral X-rays revealed a blurring of the soft parts adjacent to the metaphysis and a placement of thin bone slats suggestive of the periosteal reaction (Figure 2).

We therefore concluded, after 60 hours, that this was an early stage osteomyelitis. Intravenous Ceftriaxone 50 mg/Kg/d and Gentamycin 3 mg/kg slowly over 30 minutes was given for 14 days followed by Ofloxacin suspension 100 mg/5 ml 7.5 ml³ times/ day for 4 weeks. Additionally, an L-shaped plaster of Paris was placed. The pain reduction was almost immediate with VAS increasing from 7 to 4 and then from 4 to 2 within 12 hours of initiation of treatment.

Discussion

It is not uncommon for a vaso occlusive crisis to hide an underlying focal pathology. If a rapid response to analgesic treatment suggests a VOC by bone infarction, the persistence or resurgence of pain should prompt an investigation for an associated pathology to initiate appropriate treatment. Our 2 cases illustrate that this is the only way to achieve a total remission of the crisis.

The hemoglobin abnormality caused by mutations in the heme chain and a change in the shape of red blood cells seen in situation of infections, hypoxemia, acidosis; leads to capillaries obstruction and painful bone infarctions that explains the VOC [3].

This algorithm describes steps leading to physical aspects of vaso-occlusive crises, but it does not explain what triggers the VOC. To the already known basic mechanism it is important to add te recent data suggesting: dehydration of deformed red blood cells, their abnormal properties of adhesion to the vascular endothelium, the role of inflammatory phenomena and activation

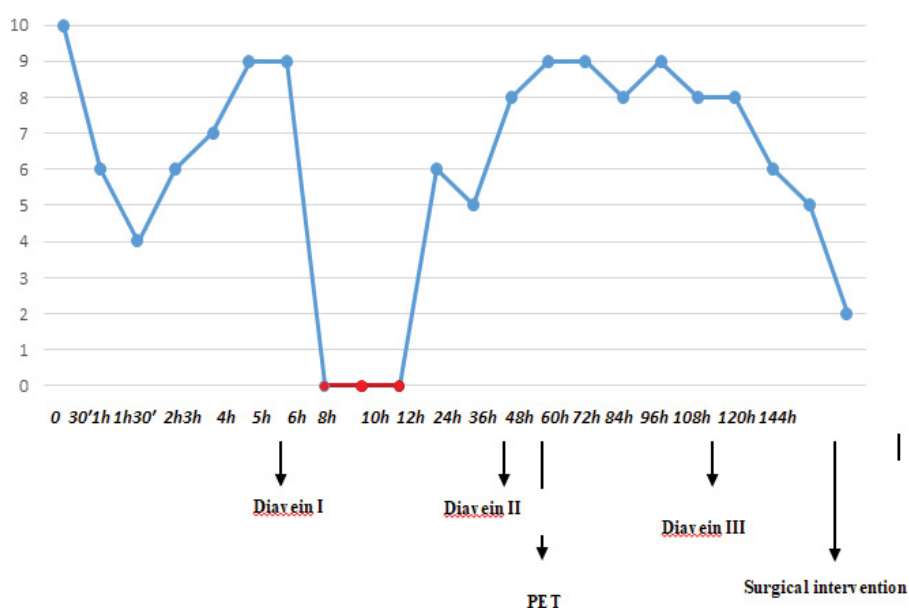


Figure 1 Evolution of the VAS during the treatment of the first case.

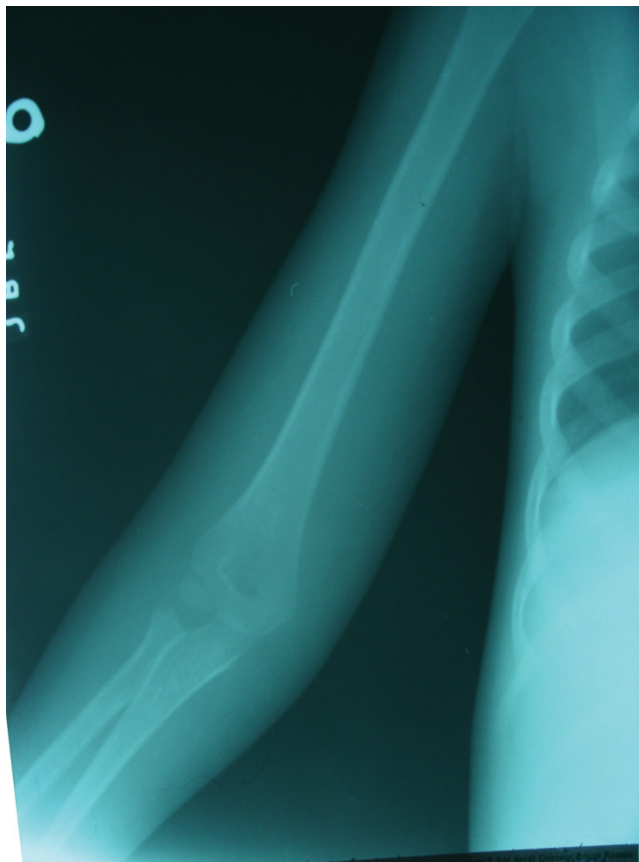

Figure 2 X-ray image of the arm illustrating the second case.

of all cells present in the vessel and finally and abnormalities of the vascular texture and NO_2 metabolism [2].

This knowledge of pathophysiology has made it possible to understand the different aspect of painful VOC and improve its management. However, in our context, the initiation of a specific procedure making rapid pain control a priority remains a goal standard; the management of VOC is not easy for many practitioners and morphine availability is extremely limited in our setup.

In any case, the management of a painful VOC is based on two major principles: A symptomatic treatment of pain and control of factors that may sustain or aggravate it [4]. This would require ruling out infections and other aggravating factors.

A continuous monitoring should be in place to avoid a progression of a VOC to an acute thoracic syndrome that would be life-threatening [5,6]. Clinical monitoring should include vital signs (temperature, blood pressure, respiratory rate, heart rate, oxygen saturation and weight) and laboratory monitoring like full blood count, platelets, electrolytes, liver enzymes, C - reactive protein and LDH must be carried out.

In case of chest pain or low SpO_2 , blood gases level is indicated in addition to a chest X-ray [3,6]. Among the pathologies that can

trigger, or mimic severe VOC are two osteo-articular complications, one of which is acute osteomyelitis, and the other chronic aseptic osteonecrosis. Osteomyelitis is the main pathology to be excluded in the presence of a bone VOC especially when there is fever associated. Acute painful bone attacks can simulate osteomyelitis same as an early osteomyelitis can be mistaken for a bone VOC. There is no clinical or biological criterion in management of sickle cell that will allow making a different between infarction and infection. Even imaging is not always unanimous because X-rays, ultrasounds and scans do not always give a clear difference between the two entities. MRI, more sensitive and specific [7] is not available in our settings.

However, high fever, painful swelling and localized and circumferential warmth are strongly suggestive of osteomyelitis especially in the presence of hyper-leukocytosis and an inflammatory biological response (ESR, CRP). The germ isolation by blood culture or the examination of the fluid aspirate from the joint can confirm the diagnosis [8].

Confirmation of the diagnosis of osteomyelitis allows for appropriate antibiotic treatment. Aseptic osteonecrosis, on the other hand, is usually associated with severe acute VOC in a person with an existing orthopedic problem of insidious evolution. Aseptic osteonecrosis of the femoral head is a common complication of sickle cell disease that particularly affects children in our settings [9] while it is considered as a long term complication in young sickle cell adult [10] it is mainly a result of intra-bone pressure. Hence the rationale behind use of decompression by drilling that allow reduction of intra-bone pressure and significantly decrease the pain as well as the progression of bone lesions [11,12].

Conclusion

The vaso-occlusive crisis is an acute phase of a chronic disease, sickle cell. Its management in the emergency room or in inpatients department must be fast, effective in controlling the pain and aiming at avoiding complications that might be deleterious for the patient. When the vaso-occlusive crisis is associated with an underlying pathology; not only must the patient be relieved, but the cause must be detected and treated. This would require optimal use of the analgesic strategies available at the treating facility.

Competing Interests

Stephanie Ngimbi Luntadila, Valentin Ngwamah Mukeba, Paul Boma Muteb and Jules Panda Mulefu performed as investigators in the clinical study from which the 2 observations were taken. The study was funded by Diavein, company owner of intellectual property on the vascular therapy device by electrical stimulation which was evaluated.

Authors' Contributions

All the authors contributed to this work. All authors also declare that they have read and approved the final version of the manuscript.

References

- 1 Devalois B (2018) Management of pain in emergency of sickle cell crisis. Proceedings of the symposium of listeners of the FMOS sickle cell university diploma 3: 52-63.
- 2 Elion J, Laurance S, Lapouméroulie C (2010) Pathophysiology of sickle cell disease. *Med Trop* 70: 454-458.
- 3 Khellaf M (2015) Vaso-occlusive crisis in sickle cell anemia. *Urgences* 5: 1-8.
- 4 Telen MJ, Wun T, McCavit TL, De Castro LM, Krishnamurti L, et al. (2015) Randomized phase 2 study of GMI-1070 in SCD: Reduction in time to resolution of vaso-occlusive events and decreased opioid use. *Blood* 125: 2656-2664.
- 5 Darbari DS, Wang Z, Kwak M, Hildesheim M, Nichols J, et al. (2013) Severe Painful Vaso-Occlusive Crises and Mortality in a Contemporary Adult Sickle Cell Anemia Cohort Study. *PLoS ONE* 8: e79923.
- 6 Galactéros F, Bartolucci P, Habibi A (2011) Medical emergencies in adults with sickle cell disease. *Urgences* 64: 733-743.
- 7 Chkoura M, Louaste J, Baaj M, Zejjari H, Rachid K (2011) Bilateral osteomyelitis of the humeral bone during drepanocytosis. *La lettre du Rhumatologue* 377: 37-38.
- 8 Aloui N, Nessib N, Jalel C, Cheluda FB, Zidi A, et al. (2005) Febrile osseous pain in children with sickle cell disease: MRI findings. *J Radiol* 86: 1693-1697.
- 9 Panda MJ (2016) Hip necrosis in sickle cell anemia (From epidemiology to treatment) - Research of the center of the femoral head. Aggregation thesis in higher and university education in medicine. University of Lubumbashi.
- 10 Mukisi MM, Bashoun K, Burny F (2009) Sickle cell hip necrosis and intraosseous pressure. *Orthop Traumatol Surg Res* 95: 134-138.
- 11 Mukisi MM, Manicom O, Alexis C, Bashoun K, Donkerwolcke M, et al. (2009) Sickle cell disease's hip necrosis: The core decompression treatment option. *Orthop Traumatol Surg Res* 95: 601-608.
- 12 Homawoo K, Bissang K, Songne B, Ayite A (1991) Sickle cell anemia and Hip necrosis. Therapeutic considerations. About 38 cases. *Médecine d'Afrique Noire* 38: 510-517.