

Complex Tibia Open Fracture with Bone Loss

Sachin Sulepetkar*

Department of Planet Metrology, Maharashtra Institute of Technology Aurangabad, India

Corresponding author: Sachin Sulepetkar, Department of Planet Metrology, Maharashtra Institute of Technology Aurangabad, India, Tel: 8310186812; E-mail: sacsulepet@gmail.com

Received date: June 29, 2022, Manuscript No. IPMCR S-22-11941; **Editor Assigned date:** July 01, 2022, PreQC No. IPMCR S-22-11941 (PQ);

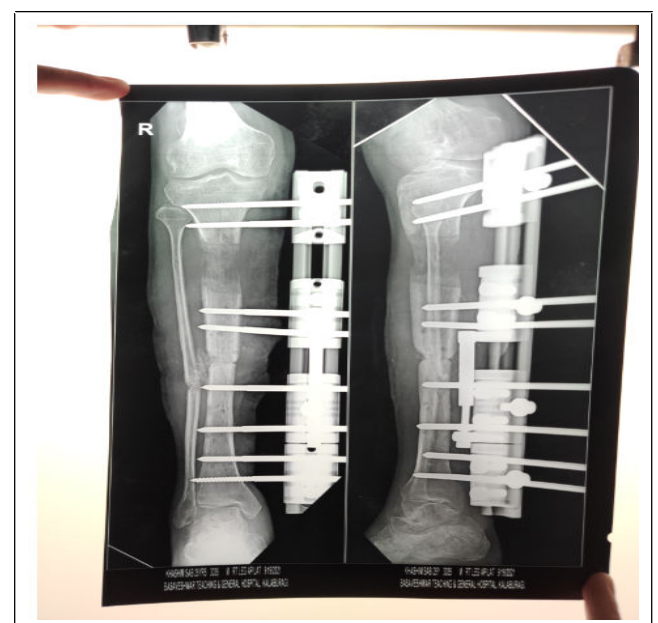
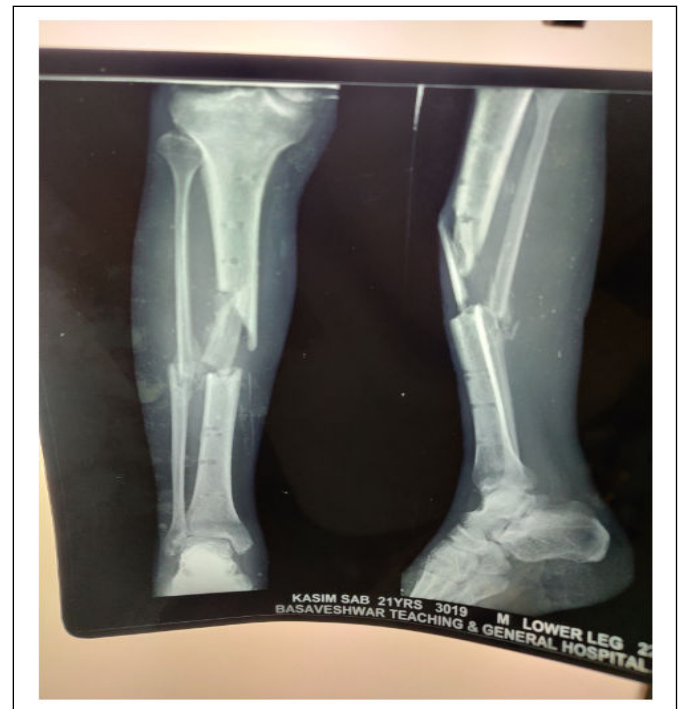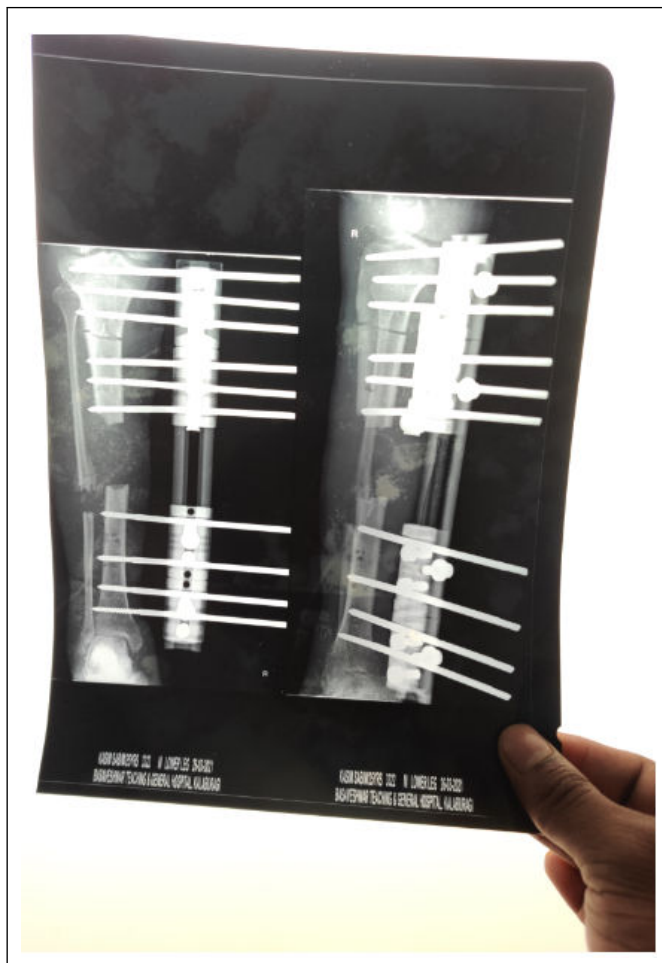
Reviewed date: July 13, 2022, QC No. IPMCRS-22-11941; **Revised date:** July 22, 2022, Manuscript No. IPMCRS-22-11941(R); **Published date:** July 29, 2022, DOI: 10.36648/2471-8041.8.7.219.

Citation: Sulepetkar S (2022) Complex Tibia Open Fracture with Bone Loss. Med Case Rep Vol:8 No:7

Description

Introduction

Presenting a case of 32 yrs old male with alleged history of run over of a tractor on right leg and sustained open injury fracture to right leg (Gustilo-Anderson type 3b with bone loss). X-ray revealed fracture right tibia with bone loss of 5cm. In this case report, we review management of soft tissue, bone loss and associated complications in complex Gustilo-Anderson type 3b fracture in a financially non-compliant patient. At 1 year follow up, patient had good functional outcome.



Conclusion

Good functional outcome can be obtained in complex open fracture (upto Gustilo- Anderson type 3b), if acted immediately with traditional surgical methods.