

Chronic Thromboemboli Pulmonary Hypertension in Patient with Eisenmenger Syndrome and Large Patent Ductus Arterius

Ke Toan Tran, Le Tra Pham*, Luan Ha Quang

Pulmonary Department, Lai general province hospital, Vietnam

*Corresponding author: Le Tra Pham, Pulmonary Department, Lai general province hospital, Vietnam, Tel: +0866677727; E-mail: leanhkado@gmail.com

Received date: February 22, 2021; Accepted date: March 08, 2021; Published date: March 15, 2021

Citation: Tran KT, Pham LT, Quang HL (2021) Chronic Thromboemboli Pulmonary Hypertension in Patient with Eisenmenger Syndrome and Large Patent Ductus Arterius. Med Case Rep Vol.7 No.3.

Abstract

Chronic thromboemboli pulmonary hypertension (CTEPH) is the group 4 of pulmonary hypertension, related to clot blocking in the pulmonary arteries in lungs. Patients with CTEPH have varies typical or atypical symptoms, which are not specific. So the diagnosis of CTEPH is a challenge to clinicians [1,2]. Chronic thromboembolic pulmonary hypertension (CTEPH) most often results from obstruction of the pulmonary vascular bed by non-resolving thromboemboli. Chronic thromboembolic pulmonary hypertension can arise in patients after acute or recurrent pulmonary emboli or deep venous thrombosis. The incidence of CTEPH is not known, but recent studies suggest that 1% to 3.8% of patients develop the condition within 2 years of acute pulmonary embolism [2]. 64-row CT of the pulmonary arteries can yield diagnostically excellent image quality and can delineate the typical angiographic findings in CTEPH such as complete obstruction, bands and webs and intimal irregularities as accurate and reliable as DSA. With additional thick MIPs it is possible to get an instant overview of the entire pulmonary arterial tree, which helps to demonstrate the pathology related of CTEPH similar to DSA [3] when the diagnosis of CTEPH is confirmed, anticoagulant should be used. Pulmonary thromboendarectomy is the most optimal therapeutic beside Pulmonary artery Balloon dilation. We found a rare case diagnosed CTEPH with Eisenmenger syndrome, large PDA by CT scanner and Echocardiography.

Keywords: Chronic thromboemboli; Pulmonary hypertension

Introduction

Chronic thromboemboli pulmonary hypertension (CTEPH) is the group 4 of pulmonary hypertension, related to clot blocking in the pulmonary arteries in lungs. Patients with CTEPH have varies typical or atypical symptoms, which are not specific. So the diagnosis of CTEPH is a challenge to clinicians [1,2]. Chronic

thromboembolic pulmonary hypertension (CTEPH) most often results from obstruction of the pulmonary vascular bed by non-resolving thromboemboli. Chronic thromboembolic pulmonary hypertension can arise in patients after acute or recurrent pulmonary emboli or deep venous thrombosis.

Case Presentation

A 51 years old female admitted for dyspnea, cyanotic, decrease of exercise capacity, cough, limb edema and right chest pain for several days. The patient was diagnosed heart failure NYHA III, hypertension, and pulmonary hypertension 1 year ago and treated with ARB, diuretic, sildenafil but she had interrupted medicines for 2 months because of financial issue. In the Emergency Room, her vital signs: BP 140/100 mmHg, HR: 130 bpm, Temperature: 37.8 Celsius degree, Respirator rate: 30 bpm Lung: crackle in bilateral fields, SPO2: 50%, Heart sound: murmur 4/6 in apex, clubbing fingers.

ECG: Sinus rhythm with ventricular rate almost 92 bpm, Right axis deviation, RBBB, pulmonary P wave (**Figure 1**). Echocardiography: EF 40%, right ventricular dilation (RVDD: 40 mm) D shape RV, Right ventricular hypertrophy, IVC: 30 mm, severe Tricuspid valve regurgitation, PAPs: 100 mmHg, dilated Pulmonary artery trunk and right pulmonary artery.

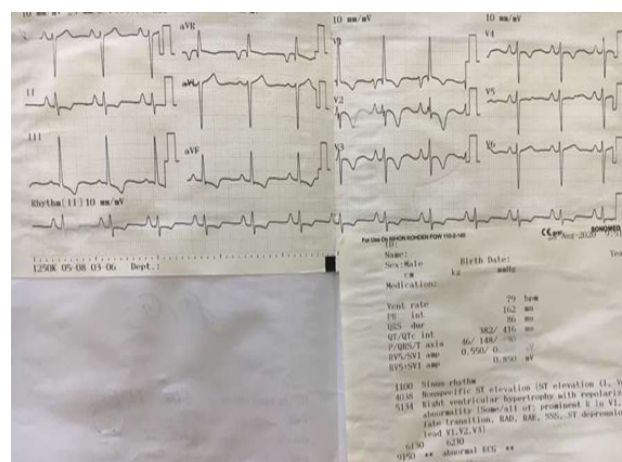


Figure 1: Sinus rhythm with ventricular rate almost 92 bpm, Right axis deviation, RBBB, pulmonary p wave

Mc'cornell sign, severe Pulmonary valve insufficient, Severe pulmonary hypertension, no left to right or right to left shunt was detective (Figures 2-5) Thoracic X-ray when admitted ER: Pulmonary trunk dilation, cardiomegaly, consolidation in inferior lobe right lung (Figure 6).

Figure 4: Severe Pulmonary valve insufficient, Severe pulmonary hypertension

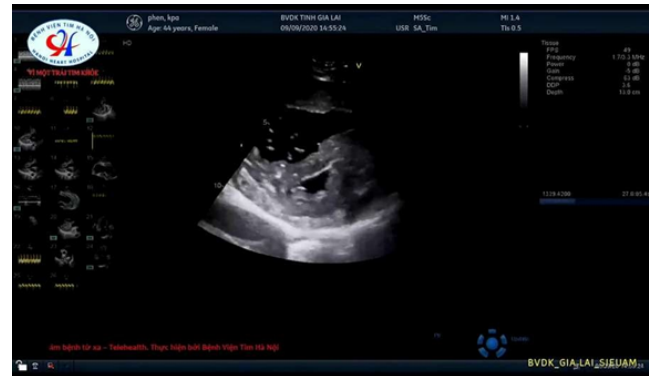

Figure 5: Right ventricular dilation (RVDD: 40 mm) D shape RV, Right ventricular hypertrophy

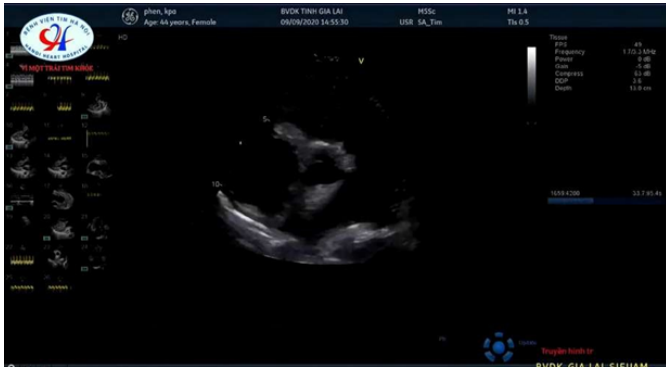


Figure 2: Dilated Pulmonary artery trunk and right pulmonary artery

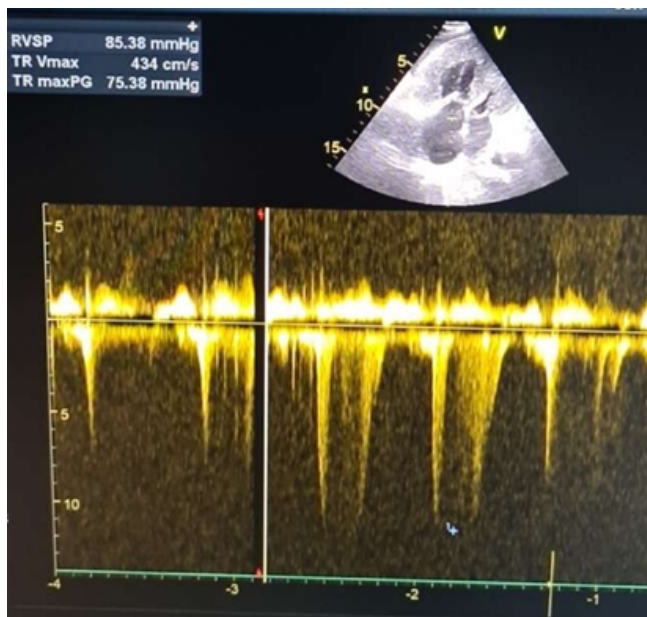


Figure 3: Severe Tricuspid valve regurgitation, severe pulmonary hypertension

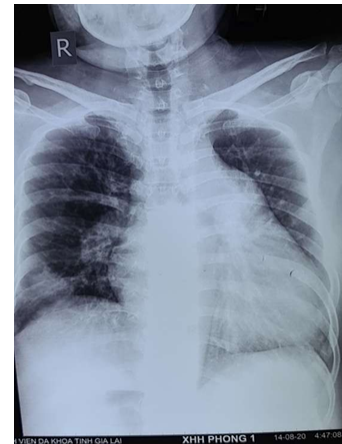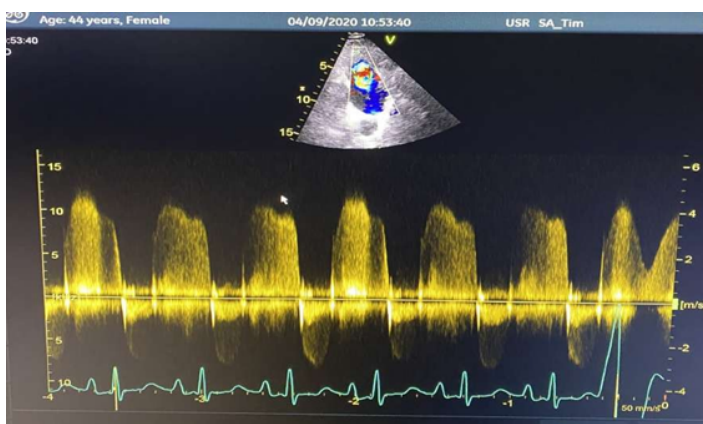


Figure 6: Pulmonary trunk dilation, cardiomegaly, and consolidation in inferior lobe right lung

Thoracic Xray after 7 days: progressive Hampton sign appears (Figure 7) Thoracic MSCT: dilated Right heart, consolidation in inferior lobe of right lung, massive thrombus in distal right pulmonary artery branch, Polo mint sign in right pulmonary artery branch, large PDA. (Figure 8-12)

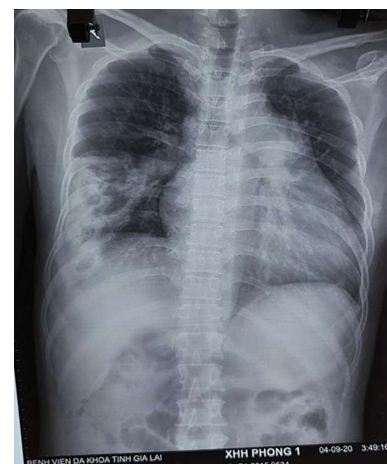

Figure 7: Progressive Hampton sign appears

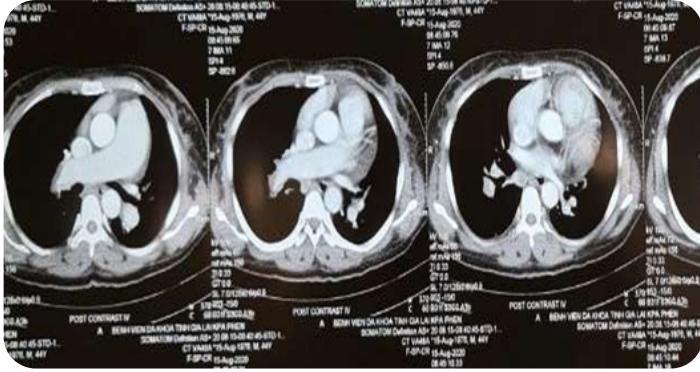


Figure 8: Dilated Right heart, dilate right pulmonary artery, massive thrombus in distal right pulmonary artery branch, Polio mint sign in right pulmonary artery branch

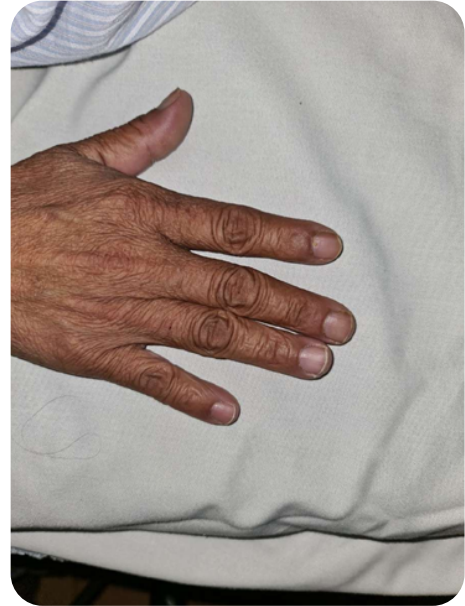

Figure 12: Clubbing fingers

The patient was treated with ARB, Diuretic, anticoagulant, CPAP, Antibiotic. After 14 days, the patient was more stable and discharged with oral anticoagulant, ARB, diuretic.

Discussion

CTEPH is defined as mean pulmonary artery pressure is more than 25 mm Hg that persists six months after acute pulmonary embolism is diagnosed. In this case, we cannot confirm precisely which is the main reason leading to CTEPH, large PDA, Eisenmenger syndrome, Hypercoagulation. But the more important thing is that the earlier we detect thrombus in pulmonary artery branch the better the patient's prognosis is. CTEPH is classified within group, and is characterised pathologically by organised thromboembolic material and by altered vascular remodelling initiated or potentiated by a combination of defective angiogenesis, impaired fibrinolysis and endothelial dysfunction. These changes lead to PH and ultimately right ventricular failure. The precise pathogenesis of CTEPH remains unclear, but appears to be incited by acute pulmonary embolism.

However, classic risk factors for venous thromboembolism do not appear to increase the risk of CTEPH and there are clear geographic differences in CTEPH epidemiology. An international CTEPH registry (Europe and Canada) indicated that 75% of patients with CTEPH had a documented antecedent history of acute pulmonary embolism, while in Japan, the rates of acute pulmonary embolism preceding CTEPH range from only 15% to 33%. There is an 80% female preponderance of CTEPH in Japan; these statistics differ significantly from the USA and Europe. A number of abnormal autoimmune, inflammatory and thrombophilia markers have been found in CTEPH patients; it is feasible that variability in this underlying pathological milieu contributes to the variability

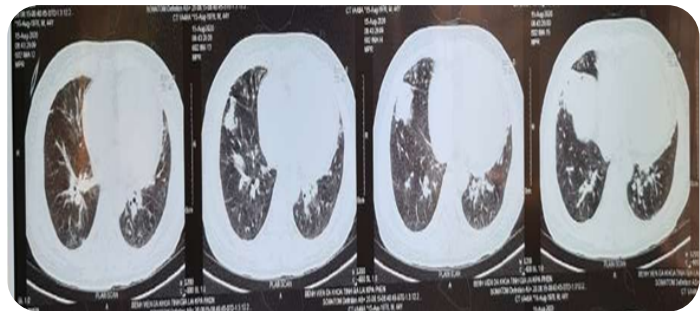


Figure 9: consolidation in inferior lobe of right lung

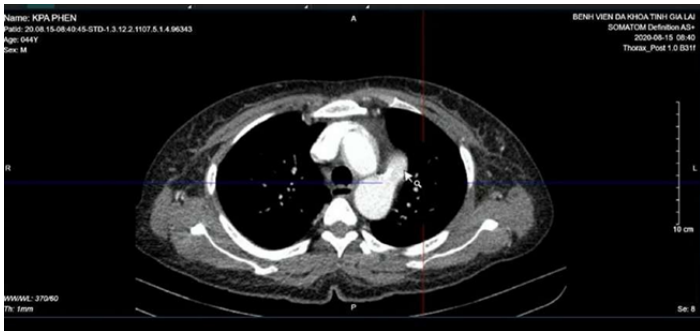

Figure 10: large PDA in axial plane (white arrow)

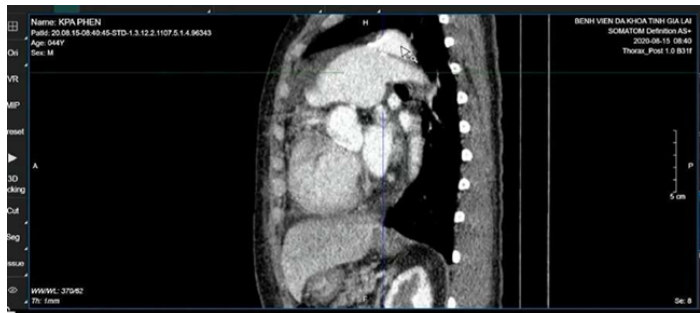

Figure 11: large PDA in sagittal plane (white arrow)

in the worldwide CTEPH epidemiology. Furthermore, variable gene expression has been demonstrated in pulmonary artery endothelial cells from patients with CTEPH compared with normal controls. In this case we can see some early criteria suggesting pulmonary artery obstruction in clinical like: Dyspnea, cyanotic, suddenly abrupt SPO₂ to 50%, ECG with RBBB and RV hypertrophy criteria that make us concern and decide to do more non-invasive imaging procedure to diagnose Bedside Echocardiogram can help us detect some sensitive criteria like: D shape RV, right ventricular dilation and hypertrophy, severe tricuspid valve regurgitation, severe pulmonary valve regurgitation severe pulmonary hypertension, dilated pulmonary trunk.

Without delay, contrast thoracic CT scanner help us to detect precisely thrombus in pulmonary artery with Polo mint sign in right pulmonary artery and large PDA. With the consultant to cardiac surgery and cardiac interventionist, we decide to treat the patient without any surgery or cardiac intervention procedures but by anticoagulation and internal medicine for long life time. We hope that anticoagulation can help to reverse the poor prognosis of this patient but according some researches, the survival rate is only 5% in 10 years with optimal internal medicine treatment.

Conclusion

From this case, we confirmed that in our rural area, there are many congenital heart diseases patients can not be detected soon after birth because of poor condition and the lack of equipment and good training cardiologists to diagnose but we are trying to do better for patients day by day in Gia Lai Vietnam.

References

1. Becattini C, Agnelli G, Pesavento R, Silingardi M, Poggio R, et al. (2006) Incidence of chronic thromboembolic pulmonary hypertension after a first episode of pulmonary embolism. *Chest* 130(1):172-5.
2. Pepke-Zaba J, Delcroix M, Lang I, Mayer E, Jansa P, et al. (2011) Chronic thromboembolic pulmonary hypertension (CTEPH): Results from an international prospective registry. *Circulation* 124(18):1973-81.
3. Reichelt A, Hoepfer M, Galanski M, Keberle M (2008) Chronic thromboembolic pulmonary hypertension: Evaluation with 64-detector row CT versus digital subtraction angiography. *European J Radiology* 71.