

## An Unusual Cause of Jaundice

Husain Taha<sup>1\*</sup>, Ebtihal Al-Yusuf<sup>1</sup>, Eman Al-Basri<sup>1</sup> and Zahra Al-Yusuf<sup>2</sup>

<sup>1</sup>Department of Endocrinology, Salmaniya Medical Complex, Bahrain

<sup>2</sup>Department of Radiology, Salmaniya Medical Complex, Bahrain

\*Corresponding author: Taha H, Department of Endocrinology, Salmaniya Medical Complex, Bahrain, Tel: +973 39639960; E-mail: husaintaha74@yahoo.com

Rec date: November 21, 2018; Acc date: December 18, 2018; Pub date: December 21, 2018

Citation: Taha H, Al-Yusuf E, Al-Basri E, Al-Yusuf Z (2018) An Unusual Cause of Jaundice. Med Case Rep Vol. 4 No.4:89.

### Abstract

**Background:** Jaundice has been reported in patients with Grave's disease thyrotoxicosis and it can occur by different mechanisms.

**Case study:** To describe a case of an 18-year-old male who presented with jaundice and thyrotoxicosis whom an extensive work up has excluded other causes of hepatic dysfunction and he improved remarkably following treatment with radioactive iodine.

**Conclusion:** Grave's disease can cause jaundice and hepatic dysfunction in which treatment of thyrotoxicosis with radioactive iodine could be a safe modality of therapy and it can cause resolution of both thyrotoxicosis and hepatic dysfunction.

**Keywords:** Jaundice; Thyrotoxicosis; Radioactive iodine

We present an unusual case of hyperthyroidism associated hepatocellular pattern of liver dysfunction in which RAI were used and cause biochemical and clinical resolution of liver damage and thyrotoxicosis.

### Case Report

An 18-year-old sickle cell trait male presented with two weeks of new onset painless jaundice and four weeks of fatigue, palpitation, hand tremor, sweating, and unintentional weight loss of 4 kg. He denied any history of fever, purities, or abdominal pain. He also denied any history of alcohol intake, intravenous drug use, smoking, travel, high risk sexual behavior, or blood transfusion. His family history was noncontributory.

Physical examination revealed a deeply icteric young male with a BMI of 24 kg/m<sup>2</sup>, resting tachycardia, hypertension, and fine tremor. He was having a goiter which was smooth, non-tender, and without audible bruit or palpable nodules. There was no evidence of graves orbitopathy or pretibial myxedema. A cardiovascular examination was unremarkable except for tachycardia. Abdominal examination was normal with no tenderness, hepatosplenomegaly or other signs of chronic liver disease.

Laboratory tests showed a hepatocellular pattern of liver injury with elevated aspartate aminotransferase (AST), 102 U/L (reference range, 10 to 30 U/L), alanine aminotransferase (ALT), 225 U/L (reference range, 10 to 40 U/L), total bilirubin (TB), 355 µmol/L (reference range, 5 to 21 µmol/L), direct bilirubin (DB), 332 µmol/L (reference range, 0 to 5 µmol/L), globulin 37 g/L (reference range, 15 to 30 g/L), hepatic synthetic dysfunction with an international normalized ratio (INR), 1.38 (reference range, 0.9 to 1.20), and normal Alkaline phosphatase (ALP) and Gamma-glutamyl transferase (GGT). Thyroid stimulating hormone (TSH) was suppressed, 0.01 ml U/L (reference range, 0.25 to 5 ml U/L), with an elevated triiodothyronine (T3) level of 30 pmol/L (reference range, 2.5 to 7.8 pmol/L), and free thyroxin (T4) level, 79.8 pmol/L (reference range, 6.0 to 24 pmol/L) (Table 1).

### Introduction

Graves' disease thyrotoxicosis classically presents with palpitations, tremor, weight loss, goiter and graves eyes disease. Rarely, thyrotoxicosis presents with painless jaundice and considerable liver dysfunction. A complex relationship exists between the thyroid gland and the liver. Thyroid hormones are important for normal hepatic function while the liver is important in the metabolism of thyroid hormone [1]. Jaundice and abnormalities in liver function tests in patients with thyrotoxicosis could be due to thyrotoxicosis itself, anti-thyroid drugs, concomitant autoimmune hepatitis, congestive heart failure, or unrelated viral hepatitis [2].

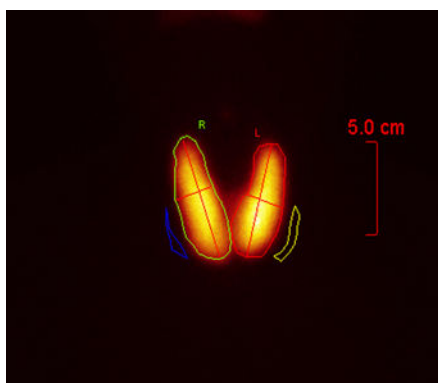
Management of patients with this presentation is challenging given that anti-thyroid drugs have been associated with drug induced liver injury. Thyroidectomy and radioactive iodine (RAI) therapy are well established alternatives, but each has its own contraindications.

**Table 1** Serial changes in values of thyroid function and liver function tests.

Test	At presentation	1 month after RAI therapy	3 months after RAI therapy	2 months after thyroxin	Reference range
TSH	0.01	0.01	55	5	0.25-5 ml U/L
FT4	79.8	23.7	2.3	20	6.0-24 pmol/L
T3	30	8.3	1	4	2.5-7.8 pmol/L
TB	355	22	4	5	5-21 µmol/L
DB	332	20	3	4	0-5 µmol/L
AST	102	16	12	14	10-30 U/L
ALT	225	36	30	34	10-40 U/L
ALP	114	64	100	102	40-129 U/L
GGT	21	25	24	25	10-71 U/L
INR	1.38	1	1.1	1	0.9-1.20
Globulin	37	34	37	36	15-30 g/L

TSH: Thyroid Stimulating Hormone; FT4: Free Thyroxine; T3: Triiodothyronine; TB: Total Bilirubin; DB: Direct Bilirubin; AST: Aspartate Aminotransferase; ALT: Alanine Aminotransferase; ALP: Alkaline Phosphatase; GGT: Gamma-Glutamyl Transferase; INR: International Normalized Ratio.

Pertechnetate thyroid scan was consistent with Graves’ disease (**Figure 1**). Extensive further testing excluded other causes of liver disease. Hepatitis A IgM antibodies, Hepatitis B surface antigen, Hepatitis B core IgM antibodies, Hepatitis C antibodies, Hepatitis E antibodies, Epstein-Barr virus (EBV) IgM and IgG antibodies, cytomegalovirus CMV IgG and IgM antibodies, anti-smooth muscle antibodies, antinuclear antibodies, anti-Liver kidney microsomal antibodies, anti-mitochondrial antibodies, ceruloplasmin, hemochromatosis screen, HIV antigen-antibody were all negative. Ultrasound of the abdomen and magnetic resonance cholangiopancreatography (MRCP) showed no biliary ductal dilatation, pancreatic, biliary, or liver masses, portal vein thrombosis or finding suggestive of primary sclerosing cholangitis. Echocardiogram was normal with ejection fraction of 64%.

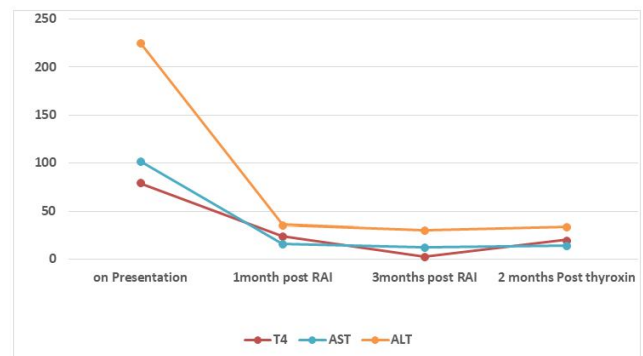


**Figure 1** Pertechnetate thyroid scan is showing an enlarged thyroid gland with an increased uniform distribution of the uptake in an estimate of 38.2% with no evidence of focal hot or cold nodule, consistent with Graves’ disease.

Propranolol was commenced. Considering his hepatocellular pattern of liver derangement, Carbimazole and

propylthiouracil were not initiated. Iodine -131 radioactive iodine therapy was arranged and received after 4 weeks. He made significant improvement clinically and biochemically and he is maintained on thyroxin 125 mcg daily, with regular follow up in the endocrine clinic. The follow up investigations are shown in **Table 1**.

**Figure 2** is showing the correlation between free thyroxin and liver transaminases over time.



**Figure 2** Correlation between T4 and liver transaminases over time.

## Discussion

Patients with Graves’ disease (GD) usually present with common manifestations such as palpitations, tremors, heat intolerance, and weight loss. However, some patients may present with unusual gastrointestinal, hematologic, neurologic, and cardiopulmonary complications [3].

Hepatic dysfunction has been described in patients with hyperthyroidism since 1874 [4]. The hepatic derangement in patients with GD ranges from mild laboratory abnormalities

without clinical features to overt hepatitis, with either hepatocellular or cholestatic injury [1]. Our patient had a hepatocellular pattern of liver impairment with raised direct bilirubin, AST, ALT, and globulin. In a retrospective study conducted on hospitalized patients about hepatic dysfunction in patients with thyrotoxicosis and not on anti-thyroid medications, 81% had some degree of hepatic dysfunction [5]. A cohort study conducted by Tiffany Y. and his colleagues on 1514 patients of thyrotoxicosis showed that the incidence of any biochemical liver tests abnormalities within 6 months of thyrotoxicosis was 39% [6]. Significant predictors of abnormal serum liver biochemical test result within 6 months of a diagnosis of untreated thyrotoxicosis were identified in this study and they were: serum TSH concentration <0.02 ml U/L, male gender, and African-American race. Biscoveanu and Hasinski have reported in their study of 30 patients with Grave's disease that liver enzymes have different rates of elevation [2]. The reported increase in liver enzymes was as followed: ALP (33%), ALT (26%), GGT (24%), AST (17%), and total bilirubin (8%).

Different mechanisms for the hepatic damage in Grave's disease have been reported. It can be induced by ischemic and hypoxic injury which resulted from the increase in metabolic rate and relative decrease in blood flow to the liver. Also, a direct toxic effect on hepatic tissues by thyroid hormones can be the contributory mechanism [7]. A common reason for jaundice in thyrotoxicosis is anti-thyroid drug induced liver injury. This was not the case with our patient as he was not previously diagnosed with thyrotoxicosis and had not received any anti-thyroid medications prior to his presentation. Other causes of liver dysfunction were excluded by extensive work up like viral hepatitis, congestive heart failure, and biliary obstruction. Moreover, improvement of liver function was only noticed after RAI ablation. This implies that the cause of jaundice and liver dysfunction was probably the thyrotoxicosis itself. Autoimmune hepatitis is one of the rare causes of jaundice in patients with Graves' disease which has a strong association with autoimmune thyroid disease. The diagnosis of which needs liver biopsy which would be indicated if raised liver enzymes persists after treatment of thyrotoxicosis.

A review of the literature reveals only a few of case reports of thyrotoxicosis associated jaundice with almost all describing an initial treatment of thionamide or RAI therapy [7-10]. Management of hyperthyroidism in patients with raised liver enzymes is a clinical challenge because anti-thyroid drugs have been associated with drug induced liver injury [11]. Propylthiouracil usually causes hepatocyte damage while carbimazole and methimazole causes cholestasis. RAI therapy and thyroidectomy are well established alternatives, but these have their associated risks and contraindications. Thyroidectomy is relatively contraindicated in these patients since near normal thyroid function is required prior to surgery. RAI therapy is more reasonable choice for patients with hyperthyroidism and raised liver enzymes. RAI causes minimal harmful effects on surrounding tissues as it's mainly concentrated in the thyroid gland [12]. The dose of radiation that is absorbed by the liver in the treatment of hyperthyroidism is very minimal [13]. In a recent publication

by Renfei Wang and his colleagues, among 2385 Graves' disease patients, liver dysfunction was present in 1552 patients and liver function was normalized in 77% of the cases 6 months after RAI [14].

## Conclusion

Graves' disease can present with hepatic dysfunction and jaundice without preexisting liver disease that complicates the therapeutic decision. Treatment with RAI ablation can lead to resolution of both hepatic dysfunction and hyperthyroidism.

## References

1. Malik R, Hodgson H (2002) The relationship between the thyroid gland and the liver. *QJM: An International Journal of Medicine* 95: 559-569.
2. Biscoveanu M, Hasinski S (2000) abnormal results of liver function tests in patients with Grave's disease. *Endocrine Practice* 6: 367-369.
3. Hegazi MO, Ahmed S (2012) Atypical clinical manifestations of Graves' disease: An analysis in depth. *Journal of Thyroid Research* 2012.
4. Habershon SO (1874) Exophthalmic goiter, heart disease, jaundice, death. *Lancet* 1: 510-512.
5. Elias RM, Dean DS, Barsness GW (2012) Hepatic dysfunction in hospitalized patients with acute thyrotoxicosis: A decade of experience. *ISRN Endocrinology* pp: 1-6.
6. Lin TY, Shekar AO, Li N, Yeh MW, Saab S, et al. (2017) Incidence of abnormal liver biochemical tests in hyperthyroidism. *Clinical Endocrinology* 86: 755-759.
7. Chawla M, Bal CS (2008) Four cases of coexistent thyrotoxicosis and jaundice: Results of radioiodine treatment and a brief review. *Thyroid* 18: 289-292.
8. Ding Y, Xing J, Qiu Z, Wang Y, Zhang Y, et al. (2015) Radioactive iodine therapy without recent anti-thyroid drug pretreatment for hyperthyroidism complicated by severe hyperbilirubinemia due to hepatic dysfunction: An experience of a Chinese Medical Center. *Endocrine Practice* 22: 173-179.
9. Hull K, Horenstein R, Naglieri R, Munir K, Ghany M, et al. (2007) Two cases of thyroid storm-associated cholestatic jaundice. *Endocrine Practice* 13: 476-480.
10. Klangjareonchai T (2012) An unusual case of hyperthyroidism associated with jaundice and hypercalcaemia. *BMJ Case Reports* 2012: bcr1120115076.
11. Leo SD, Lee SY, Braverman LE (2016) Hyperthyroidism. *The Lancet* 388: 906-918.
12. Emami B, Lyman J, Brown A, Cola L, Goitein M, et al. (1991) Tolerance of normal tissue to therapeutic irradiation. *International Journal of Radiation Oncology, Biology & Physics* 21: 109-22.
13. Melo DR, Brill AB, Zanzonico P, Vicini P, Moroz B, et al. (2015) Organ dose estimates for hyperthyroid patients treated with 131I: An update of the thyrotoxicosis follow-up study. *Radiation Research* 184: 595-610.
14. Wang R, Tan J, Zhang G, Zheng W, Li C (2017) Risk factors of hepatic dysfunction in patients with Graves' hyperthyroidism and the efficacy of 131iodine treatment. *Medicine* 96: e6035.