

## A Case Report of Occult *Echinococcus granulosus* of the Thighs

### Abstract

**Background:** This study aimed to report a rare case of occult subcutaneous muscular encopresis of the thigh.

**Case presentation:** A 68-year-old female patient residing in Barkol Kazakh Autonomous County, mainly engaged in the wool processing industry. Her main complaint was "left thigh swelling for more than 3 years, pain and discomfort for 15 days" on November 9, 2023. She found that the left side of the thigh had swollen for more than 3 years; she had no pain, itching, ulceration, or other symptoms; her swelling gradually increased in size.

**Keywords:** Echinococcosis; Hydatid disease; Hydatid cyst; Thigh; Subcutaneous muscle; Case report

### Introduction

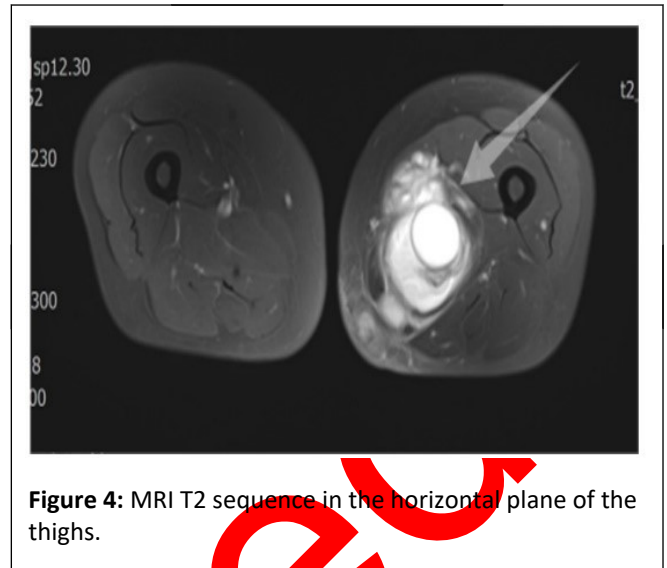
Echinococcosis, also known as hydatid disease, is a disease of animal origin that is difficult to diagnose and of great public health importance [1]. The eggs of diseased individuals are digested in the stomach and duodenum through the mouth and the six larvae escape from the shell, adsorb to the intestinal mucosa by means of small hooks and enter the small mesenteric veins through the intestinal wall to reach the portal vein system. Most of the larvae are blocked in the liver; a few can pass through the hepatic vein, the inferior vena cava, and the right heart and reach the lungs; and very few invade the circulatory system through the lungs [2]. Therefore, the liver is the most common site of parasitism, followed by the lungs, and other sites are less frequently affected. In this case, *Echinococcus granulosus* parasitized the muscle tissue of the thigh, which is an extremely rare site of parasitism compared with previous common cases of *Echinococcus granulosus* parasitism and is therefore reported as follows.

### Case Presentation

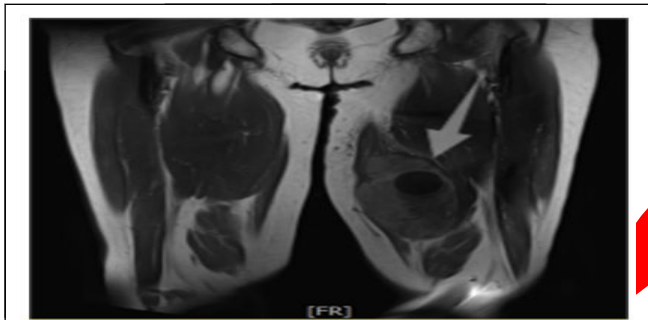
A 68-year-old female patient residing in Barkol Kazakh Autonomous County, mainly engaged in the wool processing

industry. Her main complaint was "left thigh swelling for more than 3 years, pain and discomfort for 15 days" on November 9, 2023. She found that the left side of the thigh had swollen for more than 3 years; she had no pain, itching, ulceration, or other symptoms; her swelling gradually increased in size; she was not treated; she had pain or discomfort in the last 15 days and other symptoms; and she went to the People's Hospital of Barkol County to seek further medical treatment for the superficial mass after ultrasound suggested subcutaneous solid lesions in the left inner thigh. Magnetic resonance imaging suggested that the left femoral muscle space was a large occupation, considered for the following reasons, *i.e.*, 1. An adhesive liposarcoma may be present; and 2. A synovial origin of occupation. Additionally, local doctors suggested that the patient should go to a higher-level hospital for further consultation, so that the patient came to our hospital to seek further diagnosis and treatment and was admitted to our department with a preliminary diagnosis of "malignant tumor of the left thigh". The patient's examination of both lower limbs revealed subcutaneous swelling on the posterior side of the left thigh, toughness, a size of approximately 80 × 90 mm, a symmetrical length of both lower limbs, intact skin without breakage, ulceration, erythema, or ankylosis. The patient had a history of myocardial ischemia, prophylactic oral enteric-coated aspirin 1 qd (qd: Once in a day), atorvastatin 1 qn (qn: Every night), spironolactone 1 tid (tid: Three times in a day), or danshen tablets 3 tid. For laboratory investigations, except for slight elevations in alpha-fetoprotein and ferritin levels, the remaining indices were within the normal range. MRI revealed a large cystic solid mass in the soft tissue of the left lower middle thigh approximately 90.1 × 73.3 × 119.5 mm in size, with the capsule showing a slightly shorter T1 and longer T2 signals (**Figure 1**) and part of the capsule showing a long T1 and slightly shorter T2 signals (**Figure 2**), with significant enhancement of the enhancement components and a small amount of exudation from the surrounding fat interstitial space (**Figure 3**). The morphology and signal of the left femur were normal, and no focal abnormal enhancement foci were observed in the enhanced bone. MRI revealed a large cystic solid occupying the medial soft tissue of the left middle and lower thighs, suggesting a malignant mesenchymal origin tumor (**Figure 4**). Intraoperative exploration revealed that the mass was tightly adhered to the surrounding tissues (**Figure 5**). Careful stripping

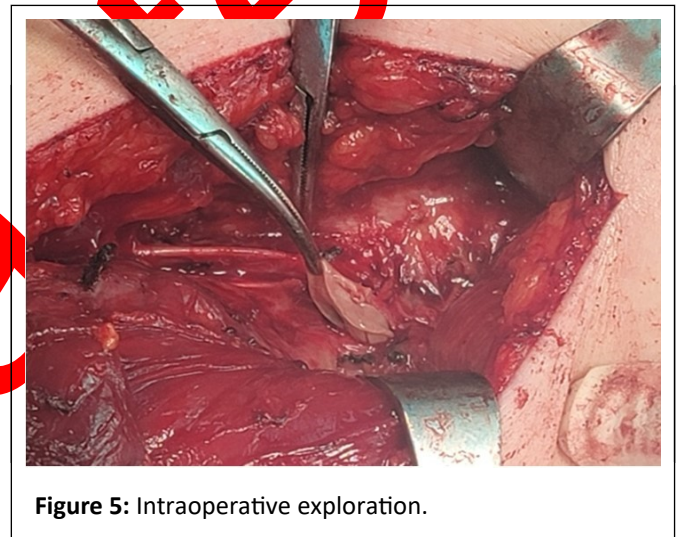
of the inner side of the mass revealed that the mass was tightly adhered to the sciatic nerve and the femoral artery. The femoral artery and the sciatic nerve were carefully stripped off, and due to the unknown nature of the mass, the possibility of malignancy could not be completely ruled out; therefore, the mass was carefully stripped off, and part of it was sent for rapid intraoperative freezing and examination during the operation. A bunch of cystic wall-like tissue in the left thigh mass (**Figure 6**) was removed. The cystic wall was 2 mm thick with a smooth, grayish wall and a total volume of  $46 \times 34 \times 8$  mm, with an additional grayish-reddish jelly like material of  $43 \times 29 \times 9$  mm (**Figure 7**). Diagnostic opinion: (Left thigh mass) Laminar arrangement of cystic wall tissues to be paraffinized except for fine-grained echinococcosis. Therefore, the swelling was encapsulated, complete stripping of the swelling was performed, and the patient was given postoperative pain relief and symptomatic treatment. Combined with multiple examinations, the patient was finally clinically diagnosed with *Echinococcus granulosus* infection of the thigh.



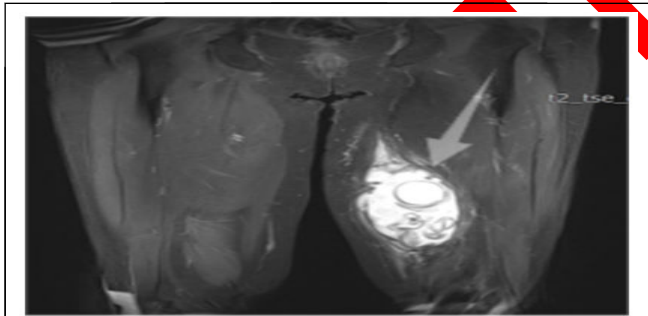
**Figure 4:** MRI T2 sequence in the horizontal plane of the thighs.



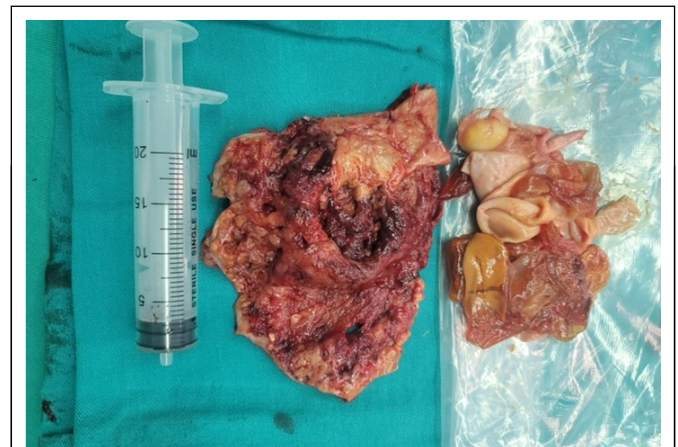**Figure 1:** MRI T1 sequence of the coronal plane of the thighs.



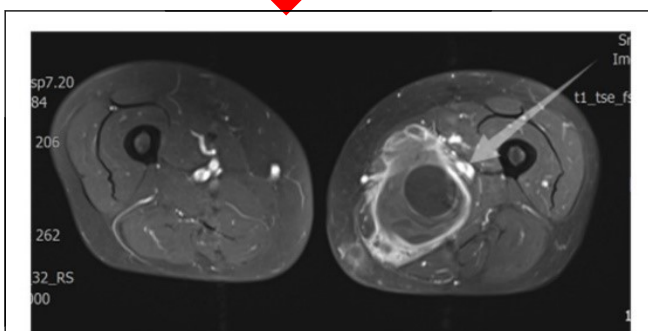
**Figure 5:** Intraoperative exploration.



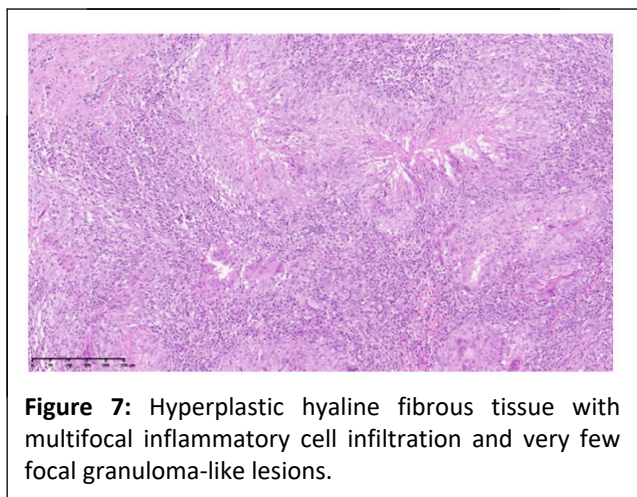
**Figure 2:** MRI T2 sequence of the coronal plane of the thighs.



**Figure 6:** Surgically resected mass with a bunch of cystic wall-like tissue. The cystic wall was 0.2 cm thick, the total volume was  $4.6 \times 3.4 \times 0.8$  cm, and another  $4.3 \times 2.9 \times 0.9$  cm of grayish-red jelly like material was observed.



**Figure 3:** MRI T1 sequence in the horizontal plane of the thighs.



**Figure 7:** Hyperplastic hyaline fibrous tissue with multifocal inflammatory cell infiltration and very few focal granuloma-like lesions.

## Results and Discussion

Echinococcosis, also known as hydatid disease, is a very dangerous zoonotic cestode disease caused by the larvae (*Echinococcus*) of the tapeworm *Echinococcus spp.* which parasitizes humans, sheep, cattle, swine and a wide range of wildlife (intermediate hosts) [3]. Fine-grained echinococcal tapeworms mainly parasitize carnivorous animals such as dogs and wolves and are infected mainly through the ingestion of organs containing echinococcal tapeworm capsules and living procephalic nodes. After ingestion, the procephalic nodes are ectopically attached to the mucosa of the canine intestinal tract and enter the adult body. At 4 to 5 weeks of development, the worms reach sexual maturity (3-6 mm in length), and the eggs or gestating arthropods are excreted in the feces and then fed on by humans or hoofed intermediate hosts (sheep, goats, pigs, cows, horses, camels). The larvae of the coccidian larvae are released from the eggs, which then move into the lamina propria, where they are passively transported through the vasculature or lymph vessels to the liver, lungs, or other organs, where the larvae of coccidian larvae develop into encapsulated cysts (crustacean larvae) [4]. Currently, four species of tapeworms of the genus *Echinococcus* are recognized taxonomically: *Echinococcus granulosus*, *Echinococcus multilocularis*, *Echinococcus oligococcus* and *Echinococcus volvulus*. The results showed that these four species of echinococcal tapeworms are morphologically distinct in their adult and larval stages and can cause different types of echinococcosis. Among them, fine-grained echinococcosis (cystic echinococcosis) and multilocular echinococcosis (alveolar echinococcosis) are the most common echinococcoses in China [5]. The high incidence of echinococcosis in China is mainly distributed in alpine meadow areas and pastoral areas with cold climates, drought and low rainfall, as well as semi-agricultural and semi-pastoral areas, of which Xinjiang, Qinghai, Gansu, Ningxia, Xizang, Inner Mongolia and Sichuan, etc. are the areas with the highest incidence of this disease [6]. This disease is characterized by regional epidemics, which are closely related to occupation, living habits, living environment, natural conditions and animal quarantine status. According to the patient's description, Patient lived in Barkol Kazakh Autonomous County in Xinjiang, which was included in the project county for the

prevention and treatment of hydatid disease in 2010 [7] and is an endemic area for echinococcosis, with serious infections of fine-grained *Echinococcus* tapeworms in domestic animals and herding dogs in the region. The patients were also mainly involved in the wool processing industry. By reviewing the relevant data, we found that similar cases occurred in Jiuyan city, Henan Province and the cause of the disease may also be related to the local fur processing industry, in which the detection rate of sheep infection is much greater than that of other livestock [8]. In this case, muscular hydatid disease was the result of a combination of the following factors. In this case, muscle worm disease is one of the rarest forms of the disease, with the liver being the main site of parasitization (75%-78%), followed by the lungs (10%-15%), and invading organs and tissues such as the mesentery, omentum, spleen, muscles, mammary glands, the female reproductive system, kidneys, bladder, brain, thorax, heart, bones, orbitals and the thyroid gland [9]. The prevalence of subcutaneous muscles is not well established, but we estimate it to be approximately 2% [4]. Subcutaneous muscle echinococcosis can be categorized as secondary or primary, with secondary echinococcosis usually presenting in at least one of the common sites of echinococcosis, such as the liver, lungs, or spleen [10]. In these cases, the onset of the disease was limited to the inner thighs, so it can be diagnosed as a primary form of hydatid disease; however, due to the lack of specific clinical manifestations, it is difficult to directly confirm the diagnosis, which can easily lead to misdiagnosis and omission of diagnosis and if the treatment is not appropriate, it can lead to serious consequences [11]. The final confirmation of the diagnosis of fine-grained echinococcosis relies on pathological examination, which reveals cystic structures and powdery skin-like material composed of fibrous tissue, eosinophilic gelatinous material and necrotic material. In the case of intermuscular fine-grained echinococcosis of the lower extremities, diseases such as intermuscular hemangioma, spontaneous intermuscular hematoma, and rhabdomyosarcoma need to be considered [12]. Many factors affect the treatment of echinococcosis, such as the severity of the disease, the location of the cyst, and the presence of complications. Currently, the main treatments for echinococcosis include partial or total removal of the organ, puncture removal of the internal capsule, complete removal of the internal capsule, ultrasound-guided percutaneous puncture, or transperitoneal laparoscopic removal. Among them, the previous 3 procedures were fixed procedures, which are more widely used than the other procedures and have certain therapeutic efficacy. In recent years, the latter 2 procedures have made large breakthroughs both nationally and internationally [5]. Treatment should be based on complete removal of the internal capsule [13]. Intraoperative care should be used to avoid damage to the cystic cavity and prevent spillage of cyst contents, and postoperative use of albendazole can effectively reduce postoperative recurrence [14,15]. Studies have shown that the recurrence rate of postoperative albendazole is between 2% and 25% [16].

Therefore, to prevent and control hydatid disease, a variety of measures need to be taken to eliminate the threat of this disease, starting with the establishment of special control organizations. These organizations should focus on planning,

organizing, coordinating, monitoring and evaluating to ensure close cooperation and resource sharing between all levels of government and relevant departments. Second, special deformers are arranged to ensure that domestic dogs receive regular deworming treatment, which lays the foundation for effective control of the source of echinococcal infection and reduction in the incidence of echinococcosis. Moreover, regular testing of dog feces was carried out to evaluate the effectiveness of the program. In this way, problems can be identified on time, and adjustments can be made according to the actual situation, thus ensuring the continuity and effectiveness of the control measures. Finally, the management and supervision of slaughtering plants should be strengthened, and strict quarantine of livestock and poultry offal should be implemented. Diseased organs that have been detected should be buried or incinerated to stop the spread of *Echinococcus* pathogens [17].

## Conclusion

On this basis, in-depth research on the pathogenesis, epidemiological characteristics, and preventive measures of hydatid disease is needed to provide a theoretical basis for its prevention and treatment. Moreover, publicity on the prevention and treatment of hydatid disease has been strengthened to guide the public to establish a healthy and civilized lifestyle and improve their awareness and self-protection ability. Through publicity and education, we will further create a favorable atmosphere for the whole society to participate in the prevention and treatment of hydatid disease.

## Announcement

- Confirmation that informed consent was obtained from all subjects and their legal guardians.
- All subjects and their legal guardians gave their informed written consent to the publication of the identifying images in an open-access online publication.
- All data generated or analysed during this study are included in this published article.
- All data generated or analysed during this study are included in this published article (and its supplementary information files).
- Funding for this project was provided by Sichuan University.

## Acknowledgement

Written consent was obtained from the patient or their relative for publication of study.

## Authors' Contributions

All authors contributed to this work. Zhou Ruixin, Zhou Wenzheng and Zhao Qingbin were all involved in clinical diagnosis, decision-making, treatment and operative intervention, postoperative care of the patient and/or the preparation of this manuscript. All authors read and approved the final manuscript.

## Competing Interests

The authors declare that they have no competing interests.

## References

1. Cadavid RAM, Yang YR, McManus DP, Gray DJ, Giraudoux P, et al. (2016) The landscape epidemiology of echinococcoses. *Infect Dis Poverty* 5: 13.
2. (2021) Basic research on the pathogenic mechanism of encapsular disease and the development of new drugs. *Journal of Xinjiang Medical University* 44: 261.
3. Meng Q, Qiao J (2023) Epidemiology and prevention and control strategies of encoprosis in Xinjiang. *Progress in Animal Medicine* 44: 112-116.
4. McManus DP, Zhang W, Li J, Bartley PB (2003) Echinococcosis. *Lancet* 362: 1295-1304.
5. Yerjiang S, Jiang Li, Chai J (2000) Progress of research on the prevention and control of echinococcosis in China. *Chinese Journal of Parasitology and Parasitic Diseases* 5: 53-55.
6. Liu P, Li J, Li Y (2016) Analysis of the current epidemiological status and causes of encoprosis pathogen in China. *China Animal Quarantine* 33: 48-51.
7. Wu R, Wang Y (2013) Investigation and analysis of echinococcosis in Barkun County, Xinjiang from 2010 to 2012. *Disease Control and Prevention Bulletin* 28: 41-42.
8. Wu W, Wang H, Wang Q (2018) Analysis of a sample survey on echinococcosis in China from 2012 to 2016. *Chinese Journal of Parasitology and Parasitic Diseases* 36: 1-14.
9. Luo Y, Wang Z, Shao J (2016) Retrospective analysis of cases of extrahepatic encapsulation in China. *Chinese Basic and Clinical Journal of General Surgery* 23: 539-543.
10. Ahmed A, Hasan R, Pekau OA (2016) Evaluation of seismic design spectrum based on UHS implementing fourth-generation seismic hazard maps of Canada. *Int J Adv Struct Eng* 8: 411-422.
11. Yongyan B, Yicheng G, Meng (2017) A case of *in situ* recurrent giant muscle encysted disease. *Modern Medicine* 45: 1504-1505.
12. Ting W, Sweet D, Fang N (2018) A case of right lower limb intermuscular encapsulation. *China Medical Imaging Technology* 34: 158.
13. Khan A, AlSubaie R, Aljayban AA (2023) Hydatid cyst of the thigh: A report of a rare case with literature review. *Cureus* 15: e46040.
14. Sharif TAM, Bahjat AS, Mohammed AA (2019) Primary infected hydatid cyst of the thigh in a young lady; Case report with literature review. *Ann Med Surg (Lond)* 47: 32-35.
15. Mohammed AA, Arif SH (2019) Intraperitoneal rupture of large hydatid cyst of the liver containing innumerable daughter cysts after blunt abdominal trauma. *Int J Surg Case Rep* 64: 41-44.

16. Ammann RW, Eckert J (1996) Cestodes. of *Echinococcus*. Gastroenterol Clin North Am 25: 655-689.
17. Yao-Yu J, Wei-Ping W (2016) Progress in the control and research of encapsulated disease at home and abroad. Chinese Journal of Pathogenic Biology 11: 284-286-289.

Retracted