

A Bleeding Giant Abdominoscrotal Hydrocele

Li-Hsiang Chen and
Ching-Chang Leeki

Department of Medicine, Kaohsiung
Armed Forces General Hospital,
Kaohsiung, Taiwan

Abstract

In this manuscript, we report a case with a bleeding giant abdominoscrotal hydrocele, resulted from the injury to the superficial scrotal capillaries due to unbearably high pressure within the scrotum caused by ascites.

Keywords: Abdominoscrotal hydrocele (ASH); Liver cirrhosis; Ascites; Scrotal bleeding

Corresponding author:
Ching-Chang Lee

Received: November 03, 2015; **Accepted:** December 14, 2015; **Published:** December 21, 2015

Department of Medicine, Kaohsiung Armed
Forces General Hospital, Kaohsiung, Taiwan.

A 43-year-old male with alcoholic cirrhosis presented with a 6-month history of progressive abdominal distension and swelling of the left scrotum. Physical examination revealed a transilluminated, nontender, 23 × 27-cm abdominoscrotal hydrocele (ASH). Intermittent bleeding from the scrotum was noted on post-admission day 11 (**Figure 1A**). We consulted a genitourinary surgeon and initiated local treatment involving the placement of simple interrupted sutures (**Figure 1B**). Abdominal computed tomography revealed massive ascites in the peritoneal cavity, communicating with the left scrotum, which contributed to the ASH (**Figure 2A and 2B**). We applied epinephrine solution, silver sulfadiazine cream on sterile gauze pads (12.5 cm × 20 cm), and an elastic gauze bandage over the bleeding sites, which successfully controlled the bleeding. Because of the presence of

✉ tsgh11@gmail.com

Tel: +886-921-404-953

massive ascites due to liver cirrhosis, we administered diuretics (furosemide and spironolactone) and albumin, transfused fresh frozen plasma, and performed repeated abdominal paracentesis. After 4 weeks of aggressive treatment, the volume of the hydrocele finally decreased (**Figure 3A and 3B**).

The ASH in the present case was hourglass shaped and filled with abdominal components communicating with the scrotum through the inguinal canal [1]. The pathogenesis of ASH in most

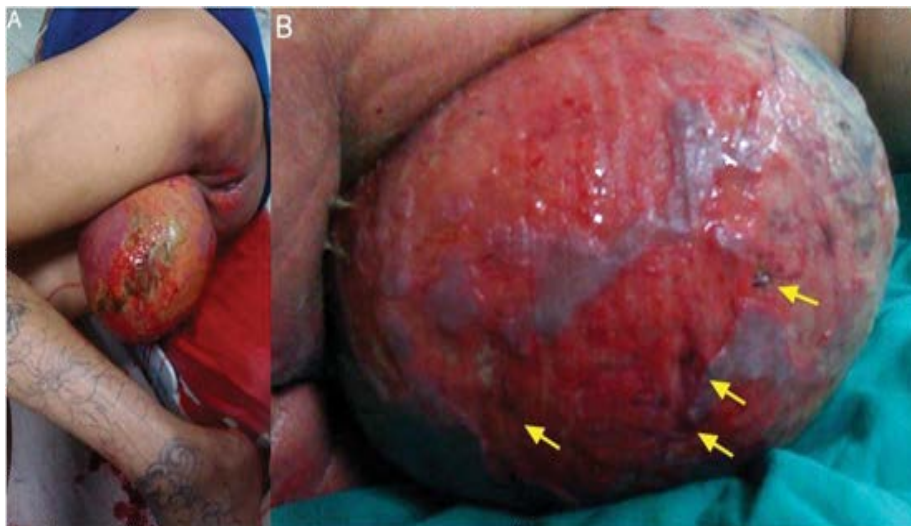


Figure 1 Bleeding from left scrotum (A), and Multiple simple interrupted sutures of the bleeding sites (B, yellow arrows).

cases is characterized by the abnormal secretion of fluid from the tunica vaginalis, which causes progressively increasing pressure within the scrotum. Fluid is transmitted through the internal inguinal ring to the abdominal cavity, resulting in expansion superiorly, in accordance with Laplace's law [1-3]. In this case, the volume of ascites flowing from the abdominal cavity to the scrotum increased the pressure within the scrotum. Spontaneous bleeding may have resulted from the injury to the superficial

scrotal capillaries due to the unbearably high pressure within the scrotum. The possibility of scrotal bleeding due to other causes such as angiokeratoma [4], hematocele, and varicocele formation were excluded. In most cases, surgical treatment of the ASH is recommended. However, surgery was contraindicated in our case due to coagulopathy caused by the liver cirrhosis. Therefore, only local treatment with sutures to control the bleeding was performed.

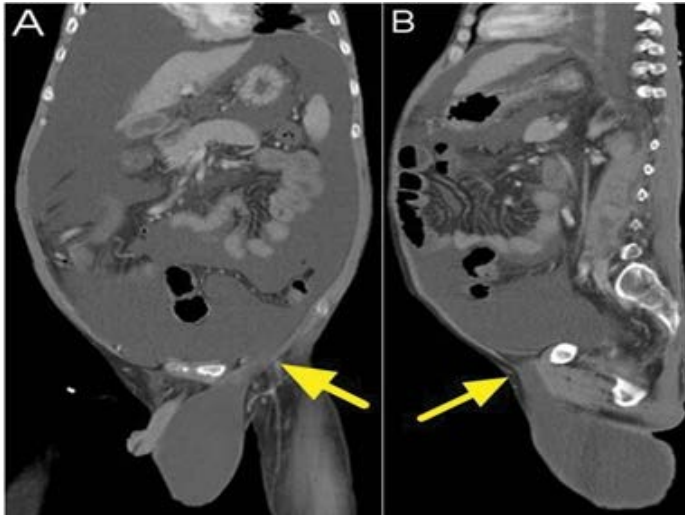


Figure 2 Computed tomography reveal massive ascites communicating between peritoneal cavity and the left scrotum through the internal inguinal ring (A, coronary view; B, sagittal view, yellow arrows).

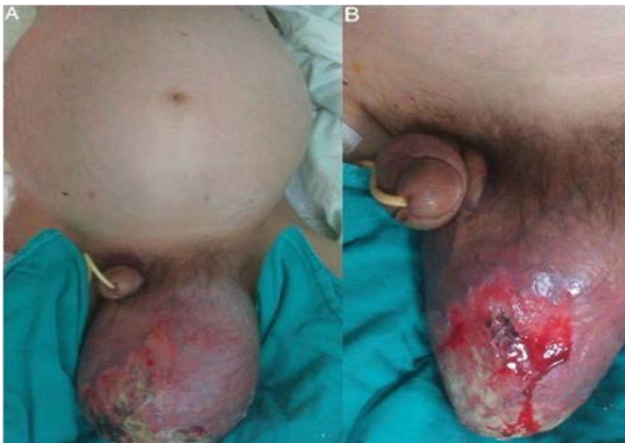

Figure 3 Photographs show the volume of the abdominoscrotal hydrocele decrease after 4 weeks of treatment (A and B).

References

- 1 Blackwell RH, Kouri A, Ellimoottil C, Bresler L, Turk TM (2013) Massive abdominoscrotal hydrocele. *Curr Urol* 2: 110-112.
- 2 Pankaj Kumar Garg, Dharmendra Prasad, Vivek Agrawal, Suchi Bhatt, Debajyoti Mohanty, et al. (2011) Abdominoscrotal hydrocele: an insight into its origin. *Hernia* 15: 587-589.
- 3 José Luis Cuervo, Héctor Ibarra, Mariana Molina (2009) Abdominoscrotal hydrocele: its particular characteristics. *Journal of Pediatric Surgery* 44: 1766-1770.
- 4 Trickett R, Dowd H (2006) Angiokeratoma of the scrotum: a case of scrotal bleeding. *Emerg Med J* 10: e57.